



DEPARTMENT OF PEDODONTICS AND PREVENTIVE DENTISTRY

KVG Dental College and Hospital

Kurunjibagh, Sullia- 574327, Karnataka, India

Phone :08257- 233148, 230608, 231089, Extn: 1211, Fax : 08257-230148

Email -[kygpedo@gmail.com](mailto:kygpedo@gmail.com), website : [kvgdentalcollege.org](http://kvgdentalcollege.org)

**1.Name:** Thejas

**Age:** 6year old

**Gender:** male

Patient gives history of autistim, developmental delay and neurological disoreder

Patient was normal until age of 2.5year old later exhibited regression in social and cognitive milestone.

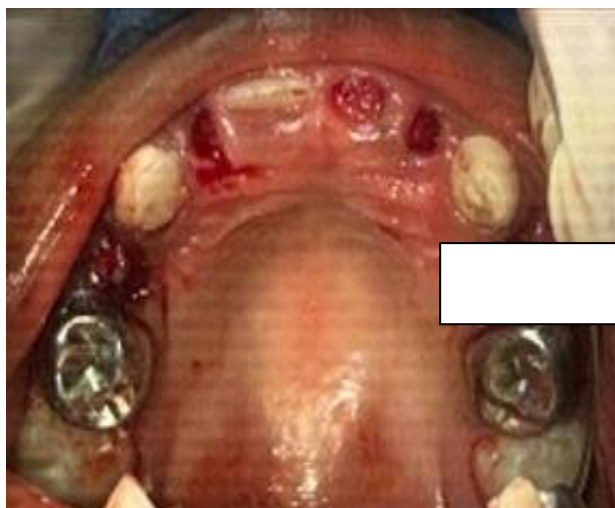
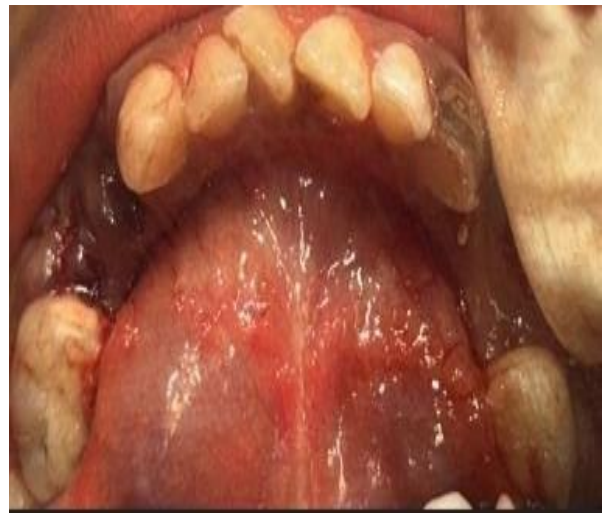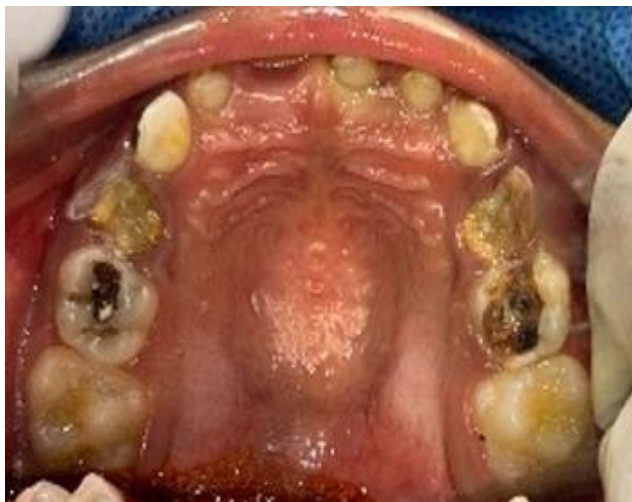Repetitive behaviour of hand flapping body rocking and running was noticed.

Patient was hypersensitive to bright light, sound.

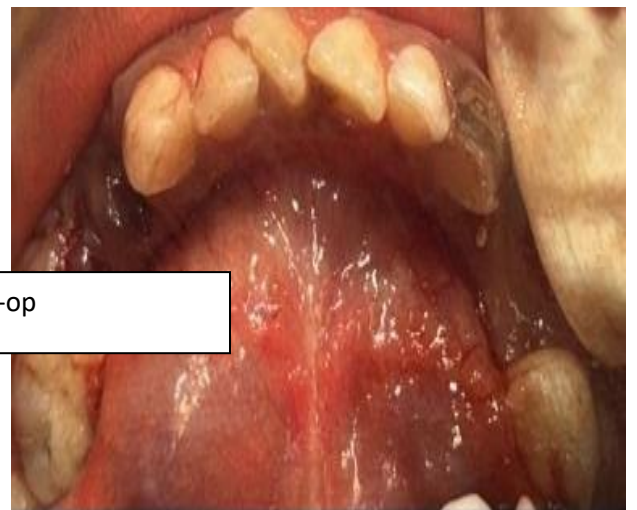Mouth mirror and nasal hood was sent to patient parents for familiarization to perform treatment under conscious sedation which was not successful.

Hence the treatment was carried out under GA.

Pre-op



Post-op





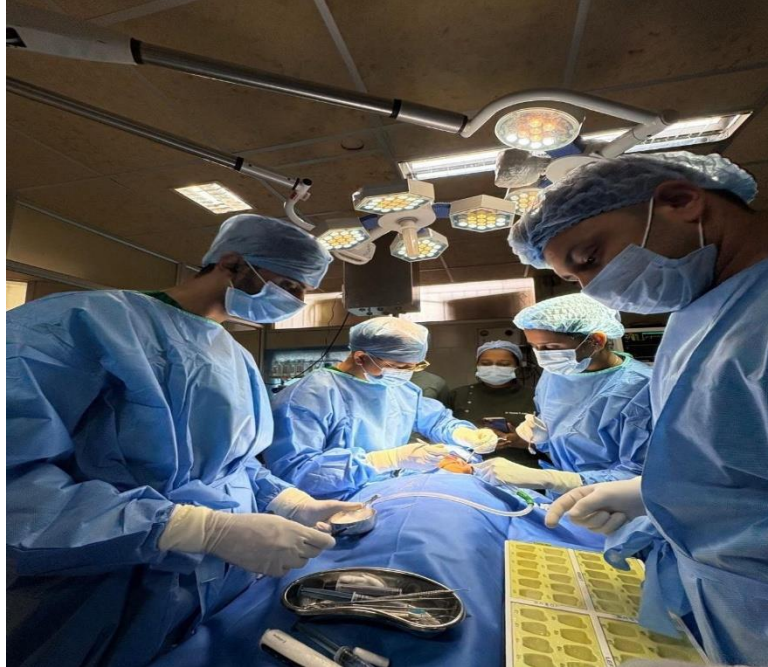DEPARTMENT OF PEDODONTICS AND PREVENTIVE DENTISTRY

KVG Dental College and Hospital

Kurunjibagh, Sullia- 574327, Karnataka, India

Phone :08257- 233148, 230608, 231089, Extn: 1211, Fax : 08257-230148

Email –[kvgpedo@gmail.com](mailto:kvgpedo@gmail.com), website : [kvgdentalcollege.org](http://kvgdentalcollege.org)



Treatment under GA

**2.Name:** Akash

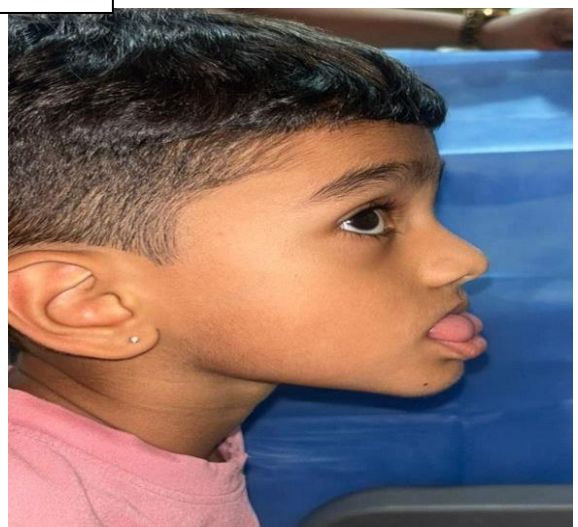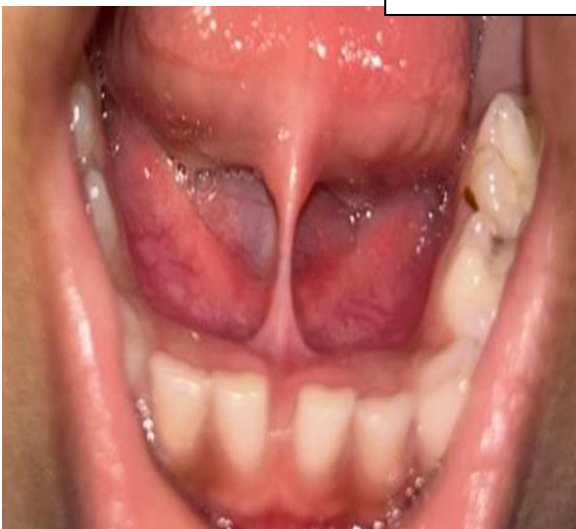
**Age:** 5 year

**Gender:** Male

**Chief complain:** Disturbed speech and pronunciation.

**Treatment done:** Laser frenectomy

Pre-op





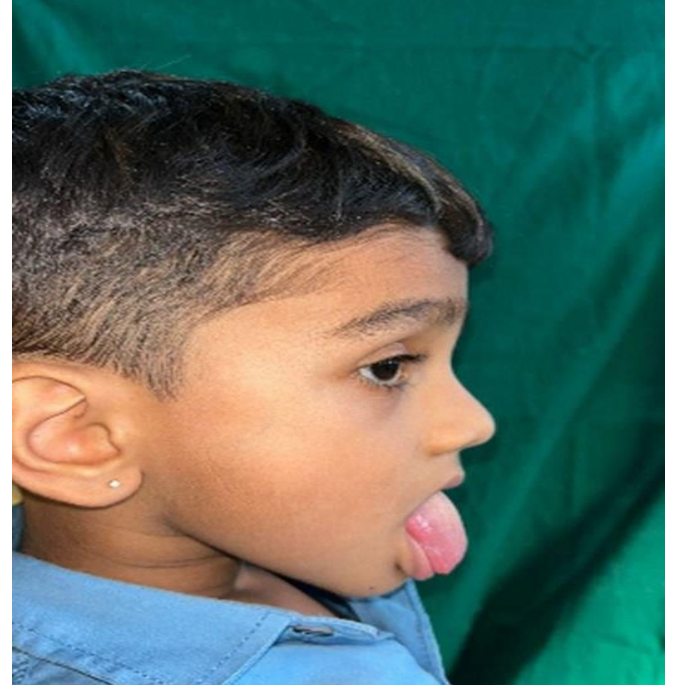
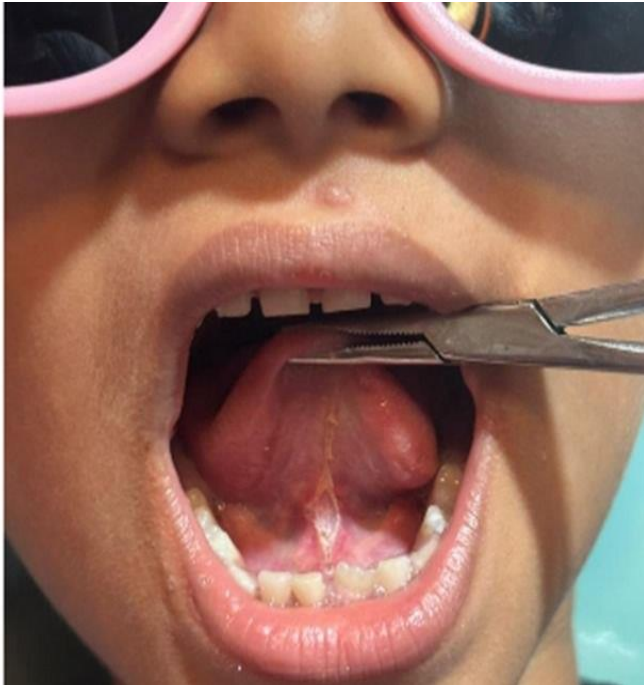DEPARTMENT OF PEDODONTICS AND PREVENTIVE DENTISTRY

KVG Dental College and Hospital

Kurunjibagh, Sullia- 574327, Karnataka, India

Phone :08257- 233148, 230608, 231089, Extn: 1211, Fax : 08257-230148

Email -[kvgpedo@gmail.com](mailto:kvgpedo@gmail.com), website : [kvgdentalcollege.org](http://kvgdentalcollege.org)



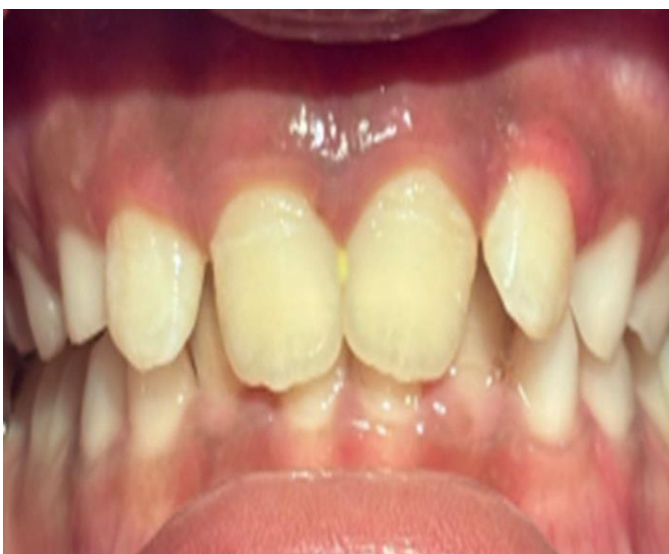Post-op

**3.Name:** Samil

**Age:** 9 year

**Gender:** Male

**Chief complain:** Deep bite in relation to anterior teeth.



Pre-op



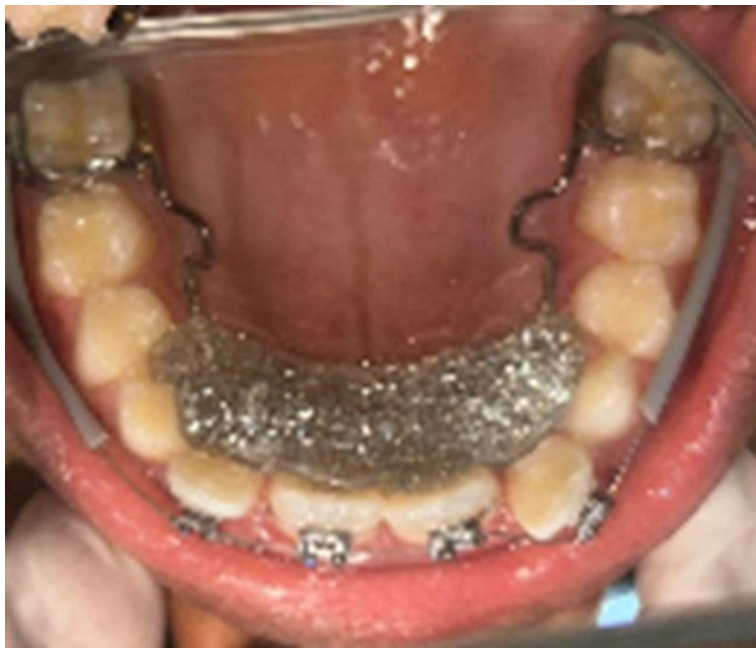DEPARTMENT OF PEDODONTICS AND PREVENTIVE DENTISTRY

KVG Dental College and Hospital

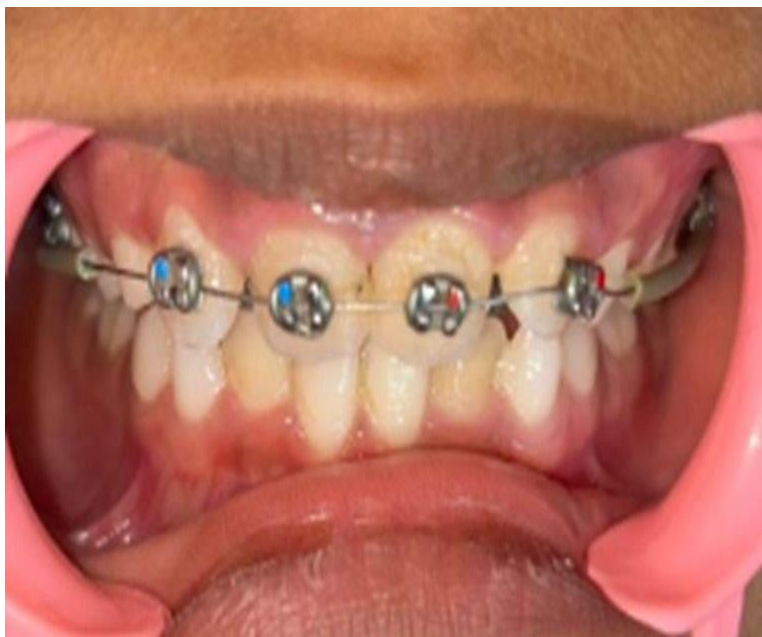Kurunjibagh, Sullia- 574327, Karnataka, India

Phone :08257- 233148, 230608, 231089, Extn: 1211, Fax : 08257-230148

Email -[kvgpedo@gmail.com](mailto:kvgpedo@gmail.com), website : [kvgdentalcollege.org](http://kvgdentalcollege.org)



Anterior bite plane for deep bite correction



2\* 4 appliance



DEPARTMENT OF PEDODONTICS AND PREVENTIVE DENTISTRY

KVG Dental College and Hospital

Kurunjibagh, Sullia- 574327, Karnataka, India

Phone :08257- 233148, 230608, 231089, Extn: 1211, Fax : 08257-230148

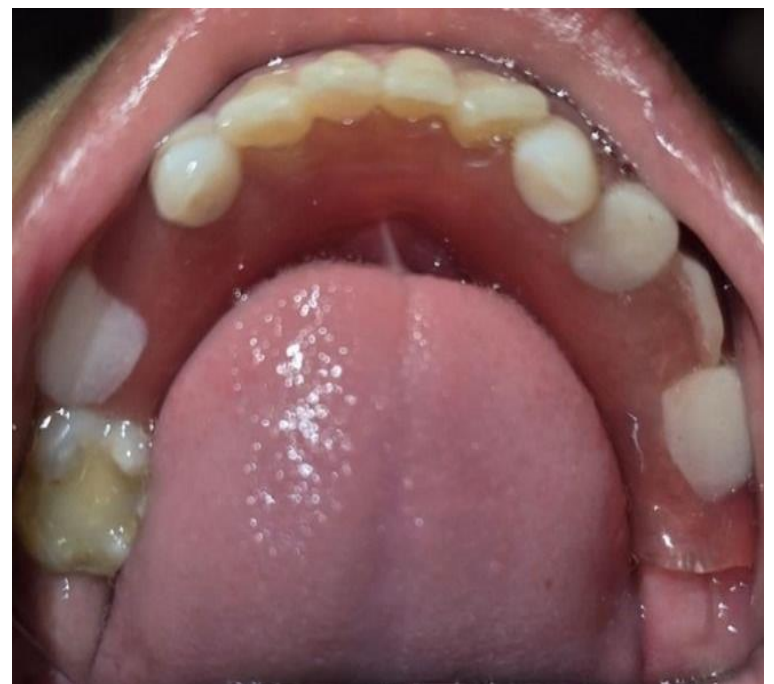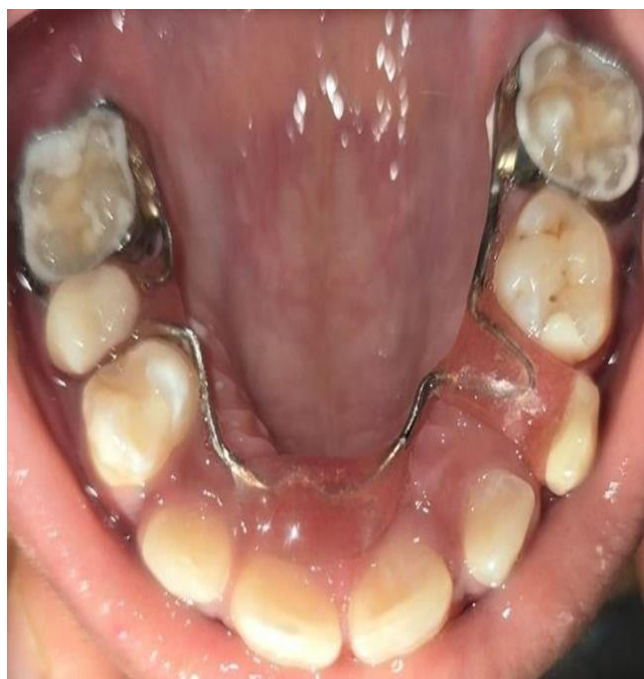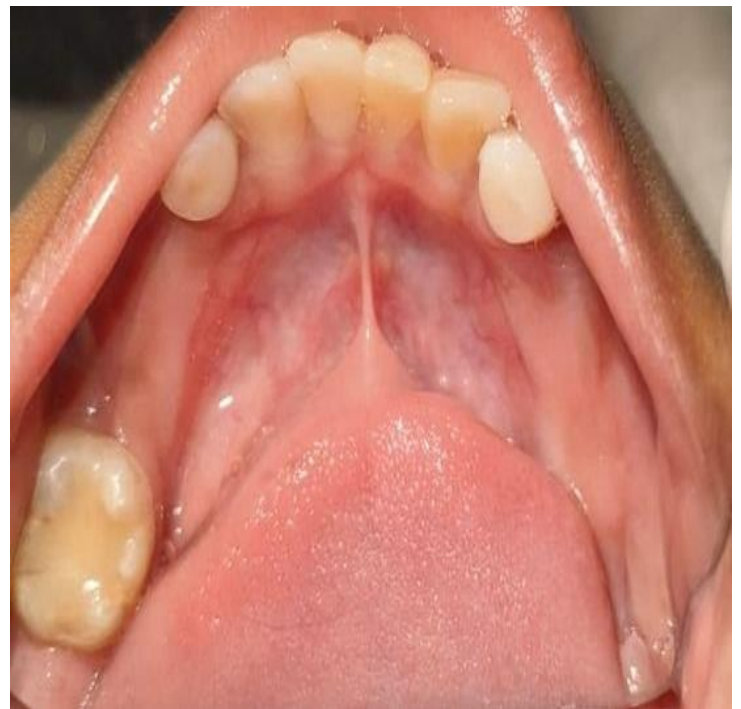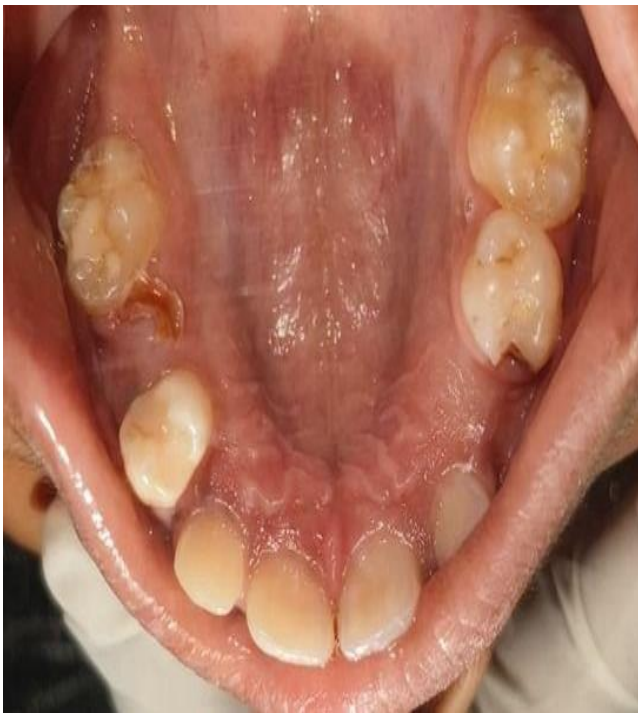Email –[kvgpedo@gmail.com](mailto:kvgpedo@gmail.com), website : [kvgdentalcollege.org](http://kvgdentalcollege.org)

**4.Name:** Abdul Fathah

**Age:** 8 years

**Sex:** Male

Management of partially edentulous area and space management in maxillary and mandibular arch





Post-operative intra-oral images after delivery of modified nance palatal arch appliance in maxilla and functional space maintainer in the mandible

**5.Name-** Thejas Kukkujadka

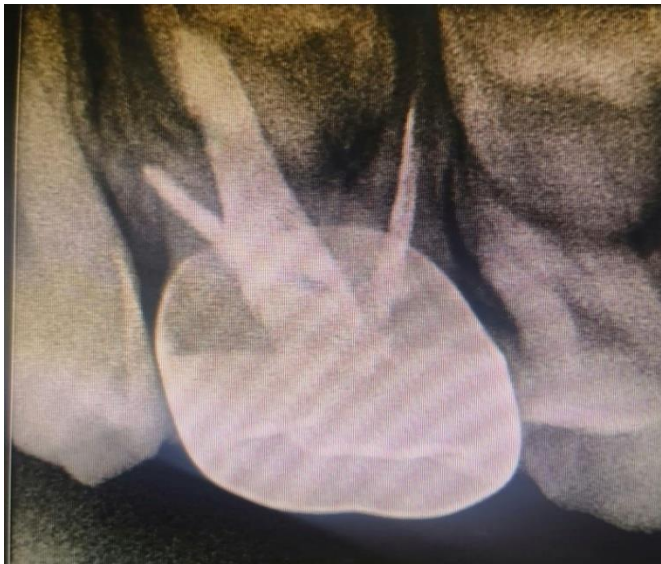**Age-**8 years

**Gender** -male

**Chief complain:** Pain in upper right back tooth region

**Diagnosis:** Chronic irreversible pulpitis

Treatment Pulpectomy followed by Stainless stell crown



**6.Name-**Ms. Fathimat Sana Ariyadka

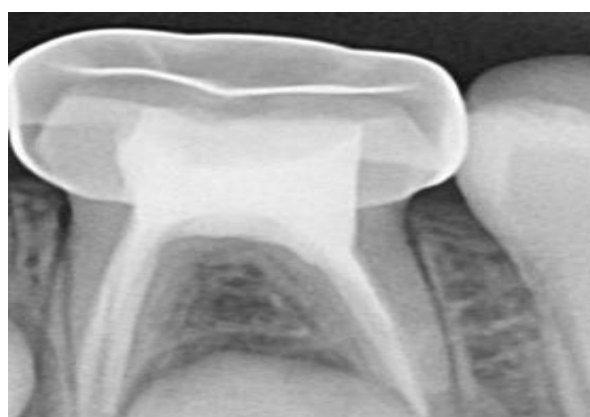
**Age-**8 years

**Gender:** Female

**Chief complain:** Pain in lower right back tooth region

**Diagnosis:** Chronic irreversible pulpitis

Treatment Pulpectomy followed by Stainless stell crown





DEPARTMENT OF PEDODONTICS AND PREVENTIVE DENTISTRY

KVG Dental College and Hospital

Kurunjibagh, Sullia- 574327, Karnataka, India

Phone :08257- 233148, 230608, 231089, Extn: 1211, Fax : 08257-230148

Email – [kvgpedo@gmail.com](mailto:kvgpedo@gmail.com), website : [kvgdentalcollege.org](http://kvgdentalcollege.org)

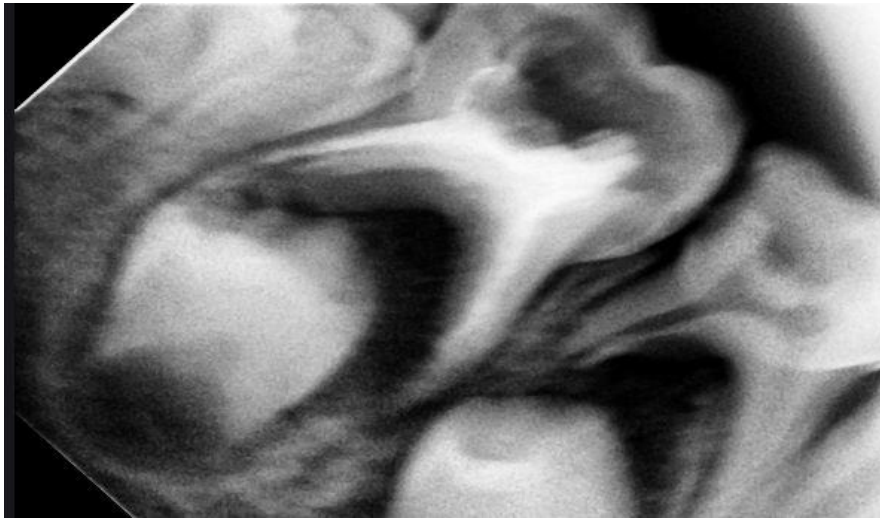**7.Name-** Ased Bellare

**Age-** 7 years

**Gender-**Male

**Chief complain-** Pain in lower right back tooth region

**Diagnosis:** Chronic irreversible pulpitis



**8.Name:** Mohammad Shayan

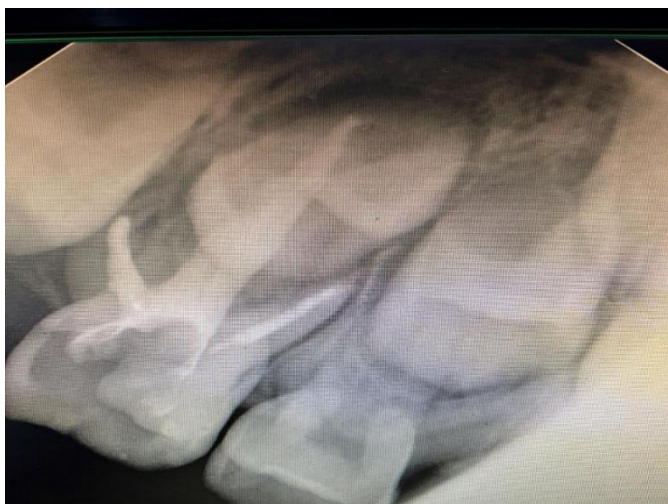**Age:** 10

**Gender:** male

**Chief complain:** Pain in upper right back tooth region

**Diagnosis:** Chronic irreversible pulpitis

**Treatment:** Pulpectomy followed by crown





**DEPARTMENT OF PEDODONTICS AND PREVENTIVE DENTISTRY**

**KVG Dental College and Hospital**

**Kurunjibagh, Sullia- 574327, Karnataka, India**

**Phone :08257- 233148, 230608, 231089, Extn: 1211, Fax : 08257-230148**

**Email –[kvgpedo@gmail.com](mailto:kvgpedo@gmail.com), website : [kvgdentalcollege.org](http://kvgdentalcollege.org)**

**9.Name:** Meenakshi Panoorkochi

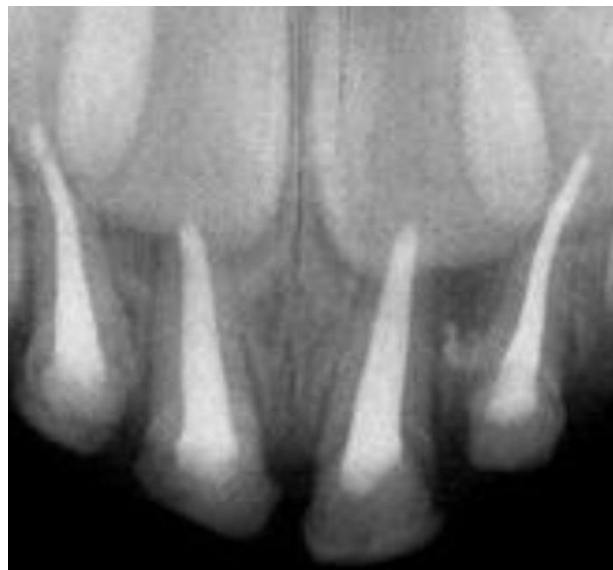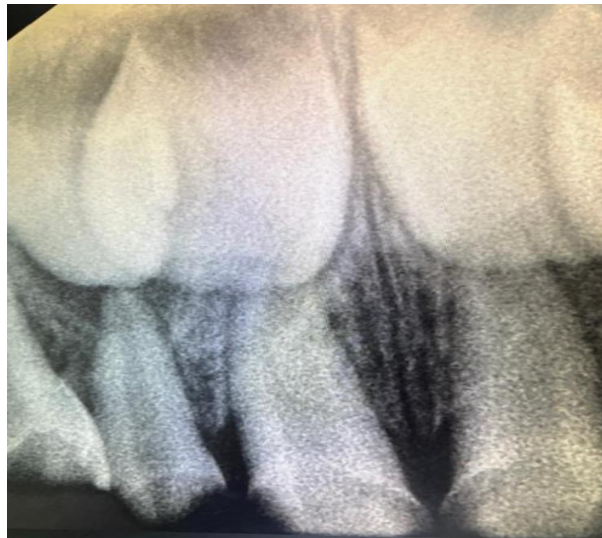**Age:**4 years

**Gender:** Female

**Chief Complain:** Pain in upper front teeth region

**Diagnosis:** ECC

Pulpectomy irt 51.52.61.62 followed by post and strip crowns





DEPARTMENT OF PEDODONTICS AND PREVENTIVE DENTISTRY

KVG Dental College and Hospital

Kurunjibagh, Sullia- 574327, Karnataka, India

Phone :08257- 233148, 230608, 231089, Extn: 1211, Fax : 08257-230148

Email - [kvgpedo@gmail.com](mailto:kvgpedo@gmail.com), website : [kvgdentalcollege.org](http://kvgdentalcollege.org)

**10.Name:** Raheema Mandekolu

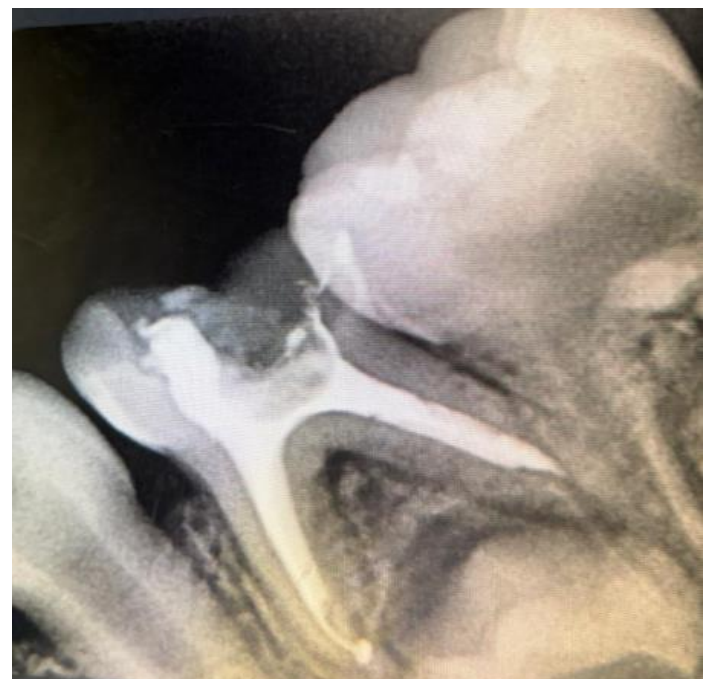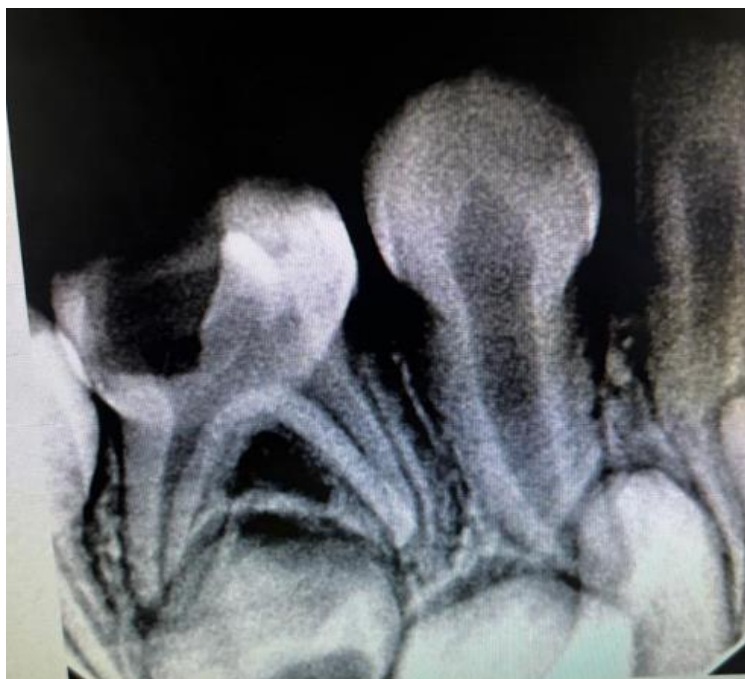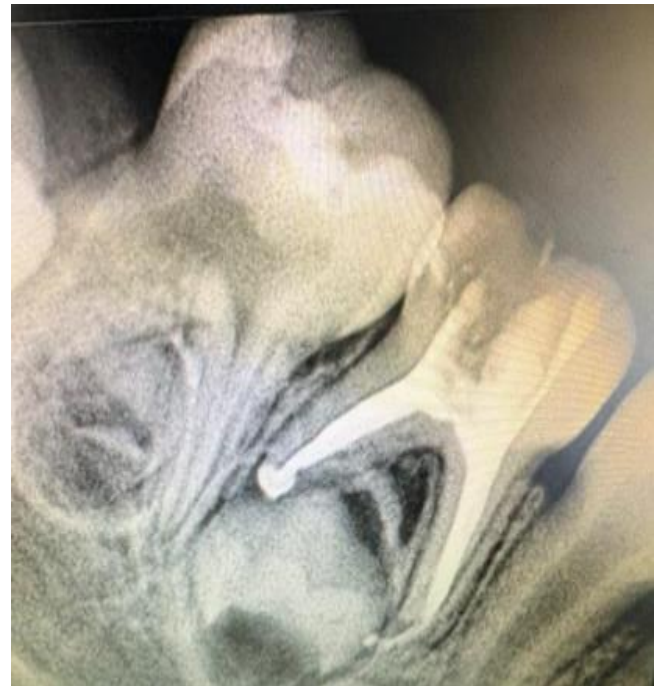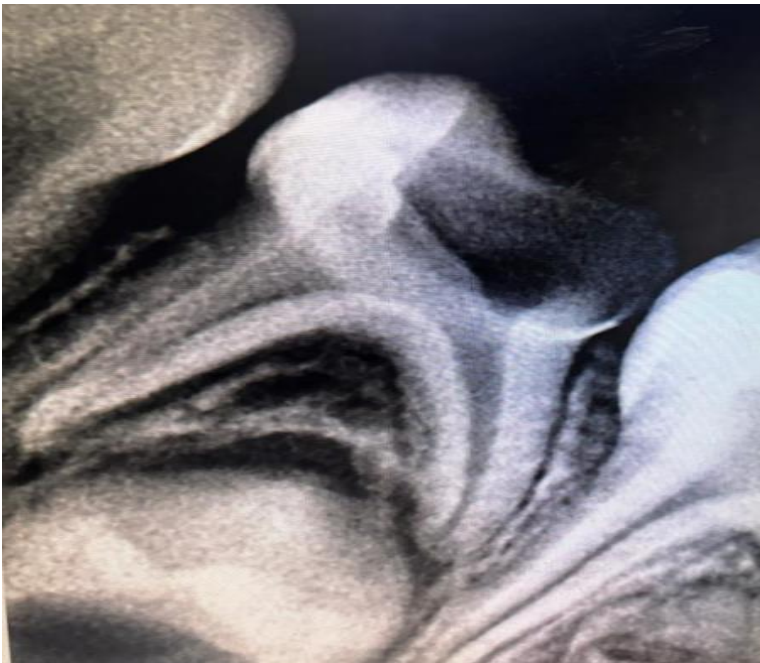
**Age:** 4 years

**Gender:** Female

**Chief complain:** Pain in lower right and back teeth region

**Diagnosis:** Chronic irreversible pulpitis

Pulpectomy irt 84, 74 followed by stainless steel crown





DEPARTMENT OF PEDODONTICS AND PREVENTIVE DENTISTRY

KVG Dental College and Hospital

Kurunjibagh, Sullia- 574327, Karnataka, India

Phone :08257- 233148, 230608, 231089, Extn: 1211, Fax : 08257-230148

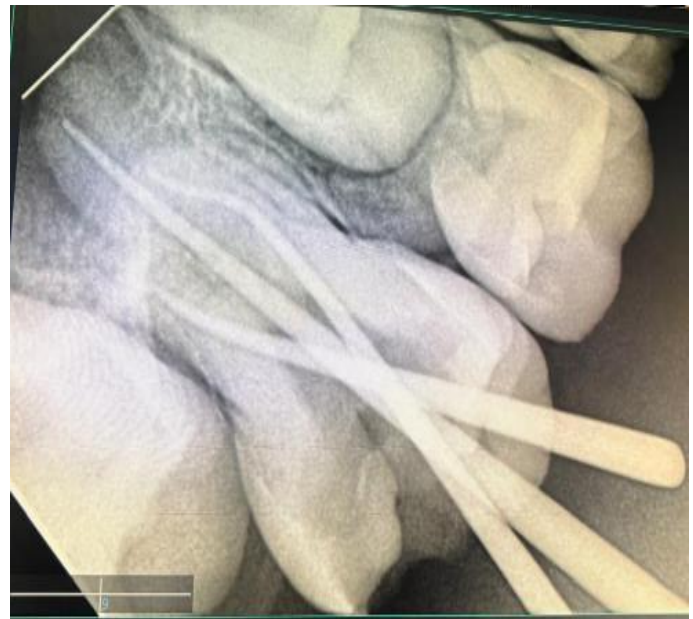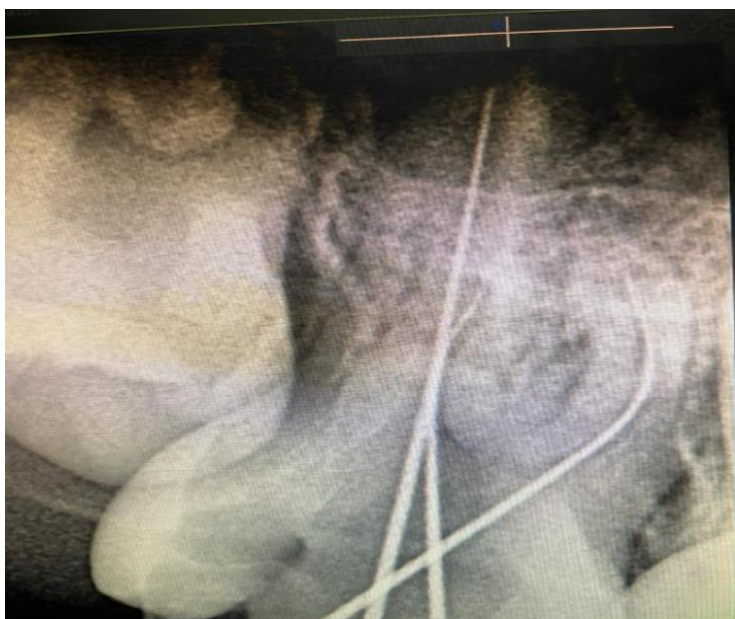Email -[kvgpedo@gmail.com](mailto:kvgpedo@gmail.com), website : [kvgdentalcollege.org](http://kvgdentalcollege.org)

**11.Name:** Rahiya Badiyadka

**Age:** 10

**Gender:** Male

**Chief complain:** Pain in upper right back tooth region

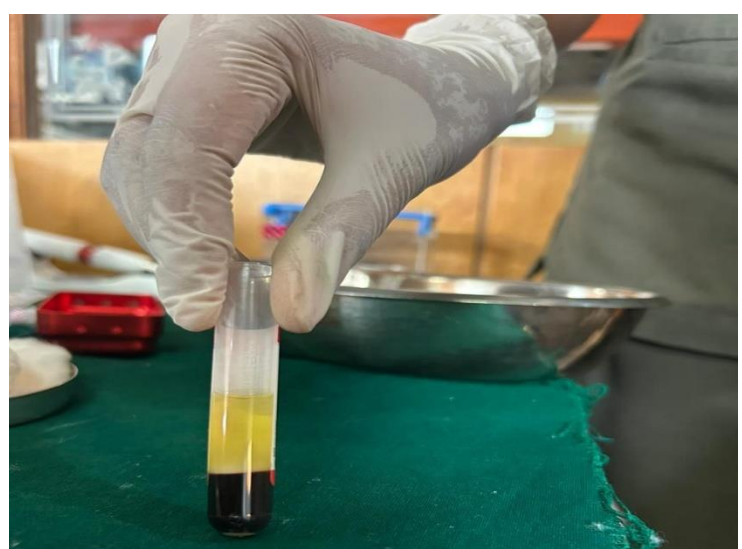
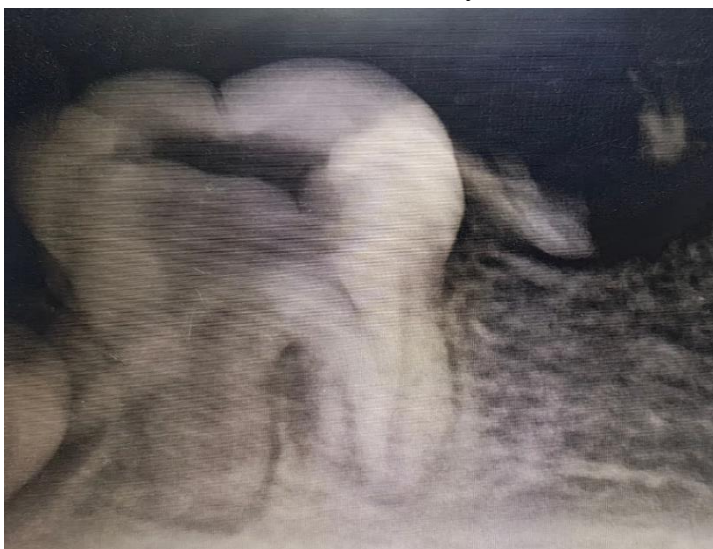
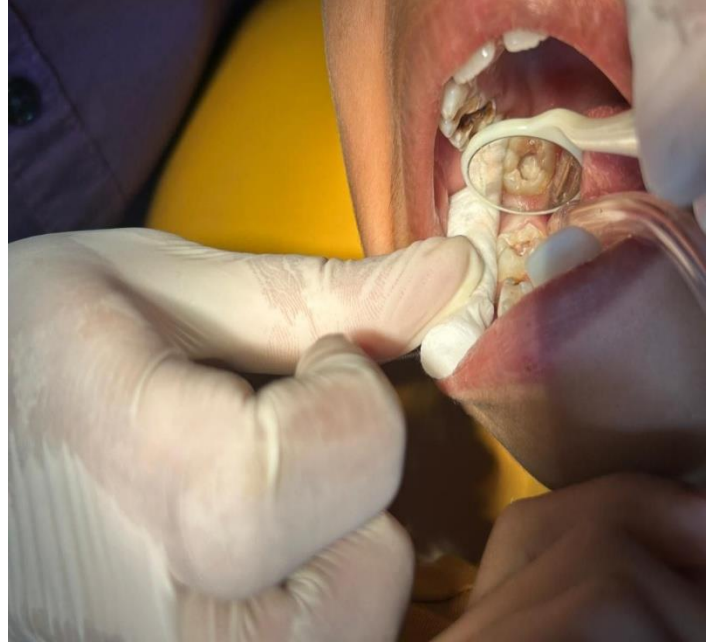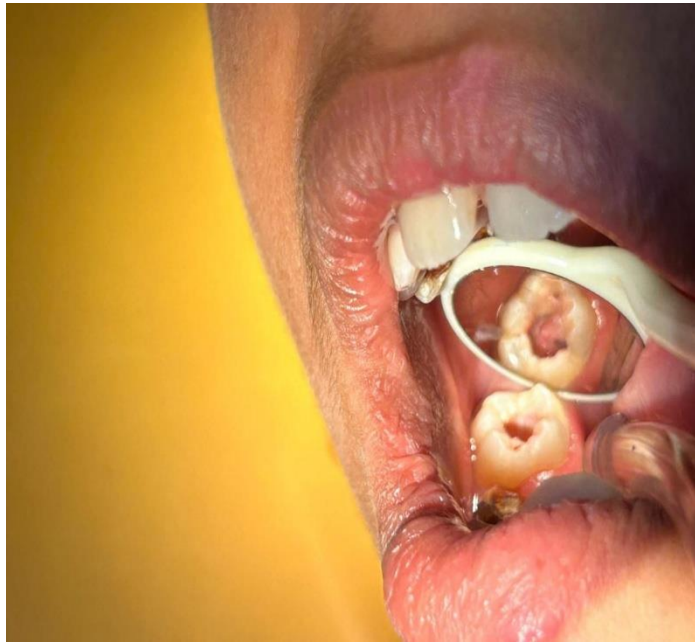12. Name -Auff

Irreversible pulpitis with immature open apex wrt 46

Treatment done-PRF

revascularization followed by MTA done wrt 46.





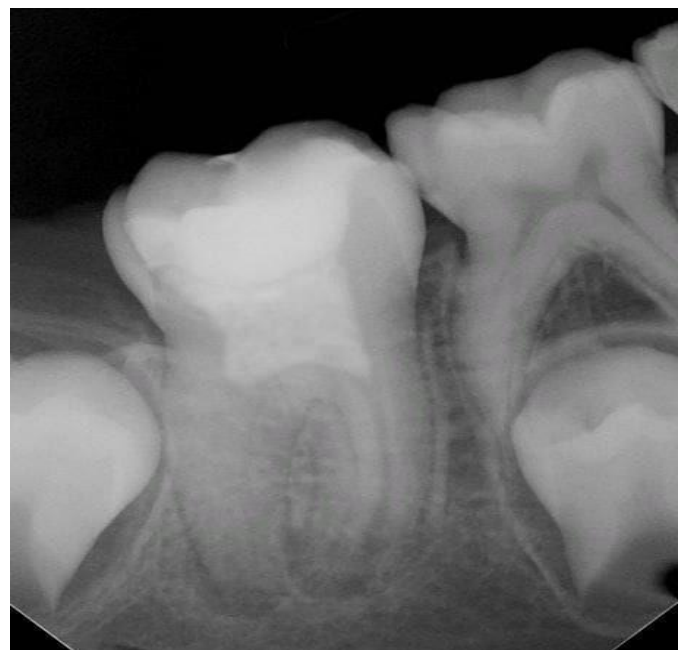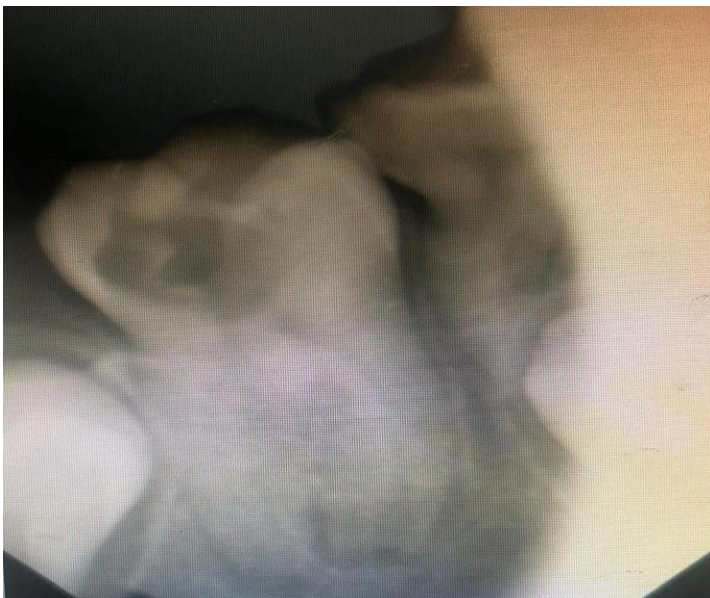13.Name: bhairoz

Age: 10 years

Gender: Male

Irreversible pulpitis with periapical abscess open apex wrt 46

Treatment done-apexification using MTA followed by gp obturation wrt 46





DEPARTMENT OF PEDODONTICS AND PREVENTIVE DENTISTRY

KVG Dental College and Hospital

Kurunjibagh, Sullia- 574327, Karnataka, India

Phone :08257- 233148, 230608, 231089, Extn: 1211, Fax : 08257-230148

Email -[kvgpedo@gmail.com](mailto:kvgpedo@gmail.com), website : [kvgdentalcollege.org](http://kvgdentalcollege.org)

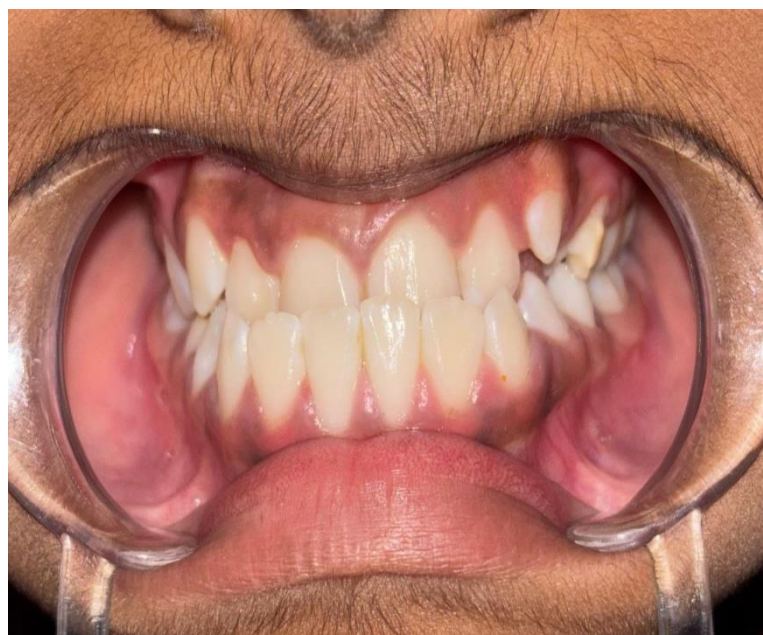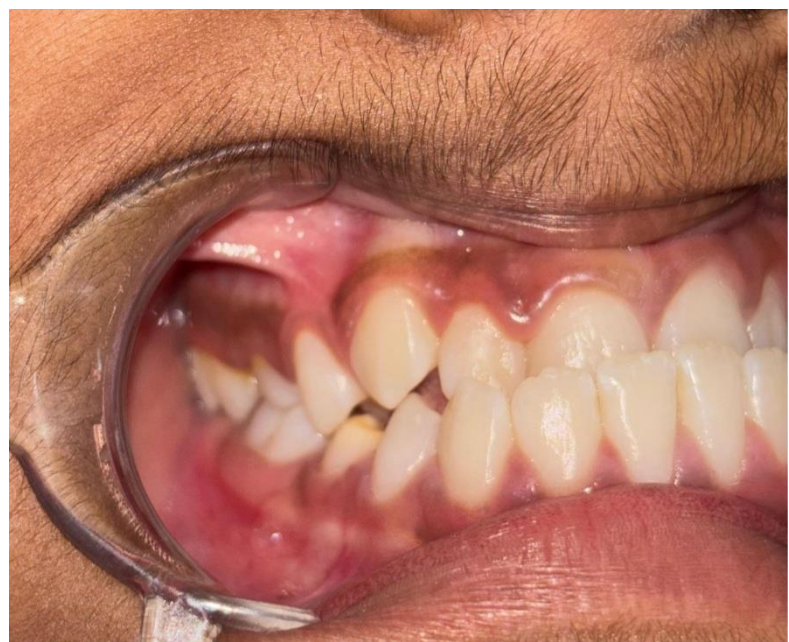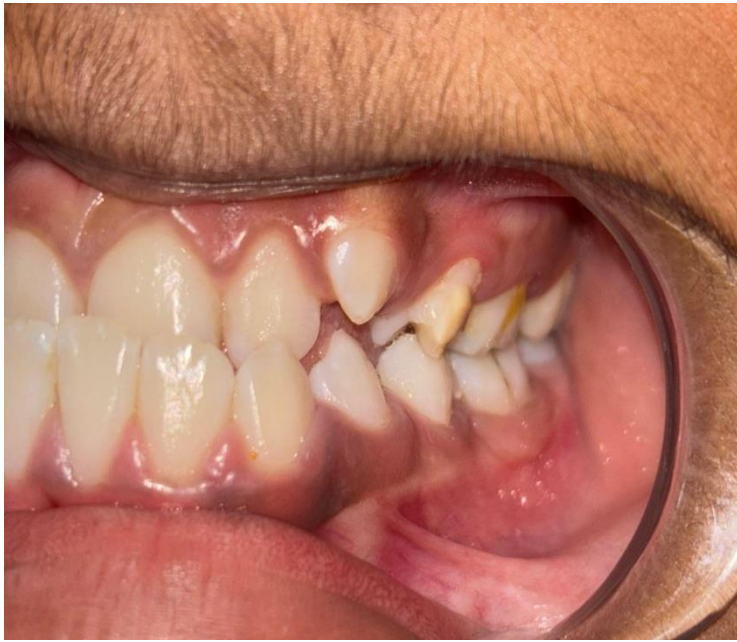14. Name: Manvisha


Age :12 yrs

Gender: female

Diagnosis: Angles class 3 malocclusion with reverse overjet of 5 mm

Treatment done: reverse twin block





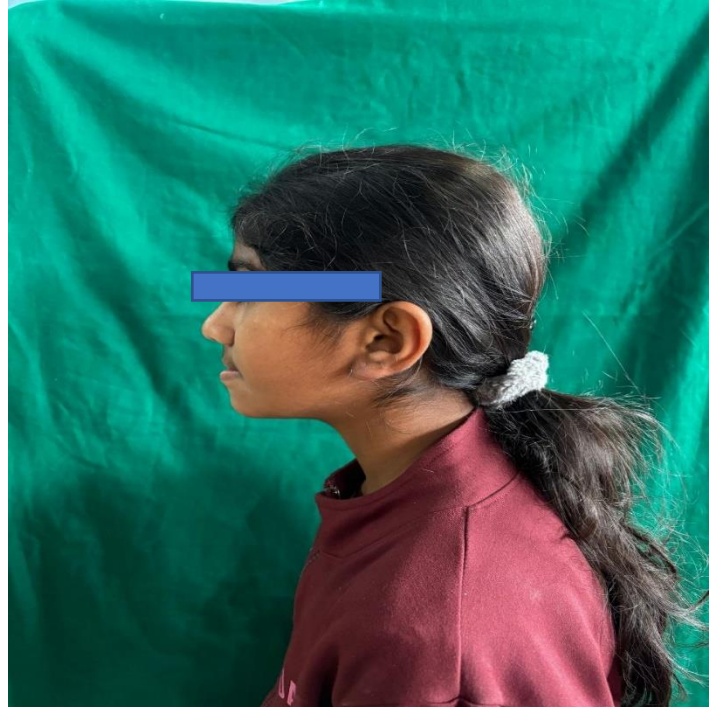DEPARTMENT OF PEDODONTICS AND PREVENTIVE DENTISTRY

KVG Dental College and Hospital

Kurunjibagh, Sullia- 574327, Karnataka, India

Phone :08257- 233148, 230608, 231089, Extn: 1211, Fax : 08257-230148

Email –[kvgpedo@gmail.com](mailto:kvgpedo@gmail.com), website : [kvgdentalcollege.org](http://kvgdentalcollege.org)





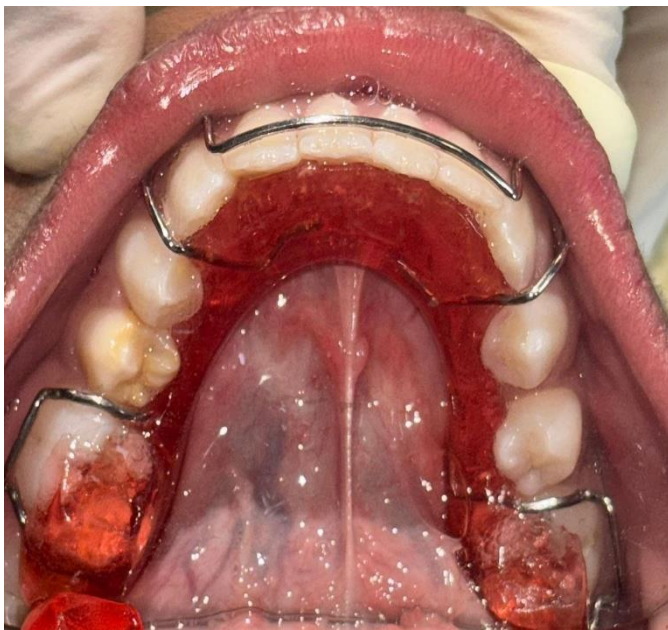
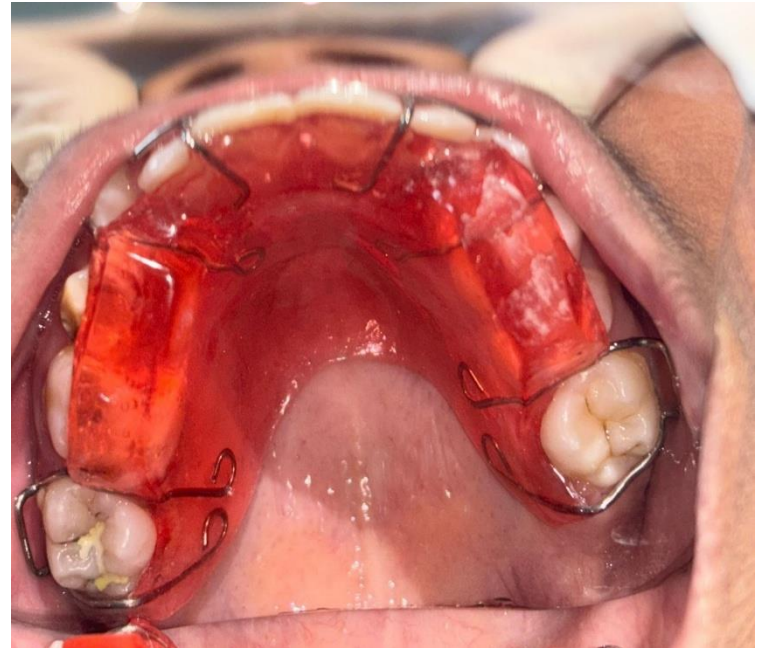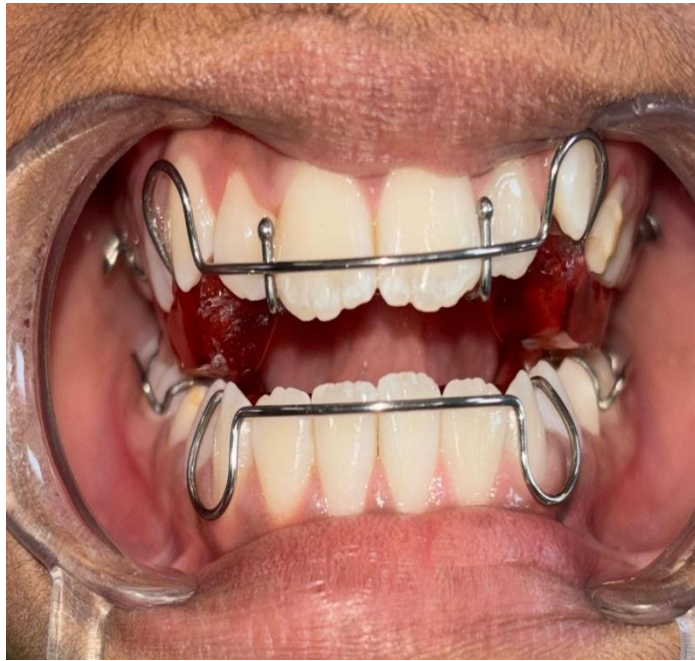
DEPARTMENT OF PEDODONTICS AND PREVENTIVE DENTISTRY

KVG Dental College and Hospital

Kurunjibagh, Sullia- 574327, Karnataka, India

Phone :08257- 233148, 230608, 231089, Extn: 1211, Fax : 08257-230148

Email -[kvgpedo@gmail.com](mailto:kvgpedo@gmail.com), website : [kvgdentalcollege.org](http://kvgdentalcollege.org)





**DEPARTMENT OF PEDODONTICS AND PREVENTIVE DENTISTRY**

**KVG Dental College and Hospital**

**Kurunjibagh, Sullia- 574327, Karnataka, India**

**Phone :08257- 233148, 230608, 231089, Extn: 1211, Fax : 08257-230148**

**Email –[kvgpedo@gmail.com](mailto:kvgpedo@gmail.com), website : [kvgdentalcollege.org](http://kvgdentalcollege.org)**

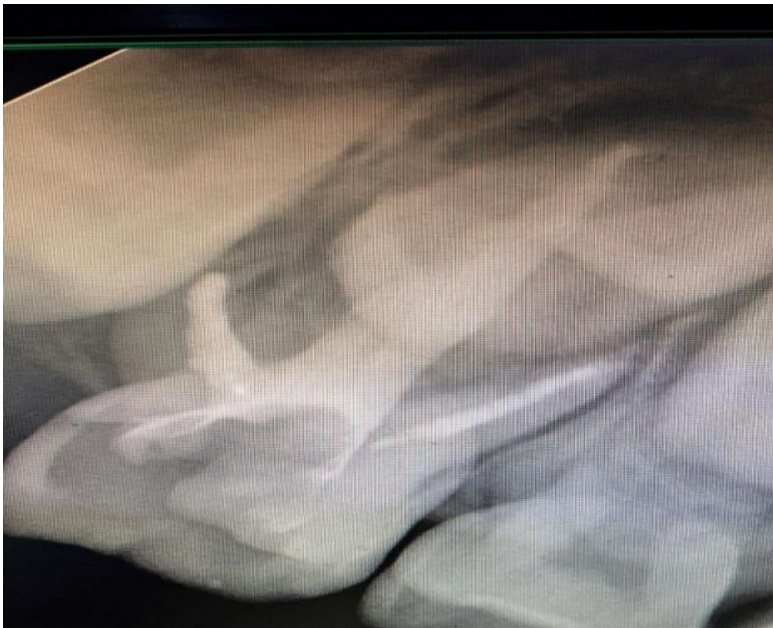15. Name: Mustaf

Age:5

Gender:male

Diagnosis: Chronic irreversible pulpitis irt 55

Treatment plan: Pulpectomy irt 55 followed by crown



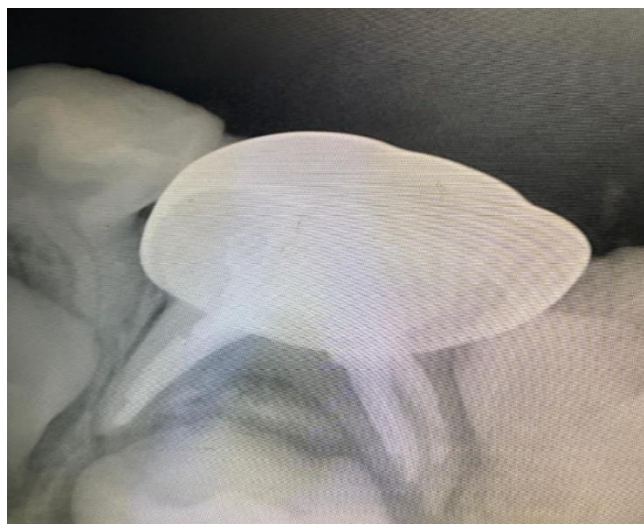16. Name: Devanshi

Age:7

Gender: Female

Diagnosis: Chronic irreversible pulpitis irt 75

Treatment plan: Pulpectomy irt 75 followed by crown





**DEPARTMENT OF PEDODONTICS AND PREVENTIVE DENTISTRY**

**KVG Dental College and Hospital**

**Kurunjibagh, Sullia- 574327, Karnataka, India**

**Phone :08257- 233148, 230608, 231089, Extn: 1211, Fax : 08257-230148**

**Email –[kvgpedo@gmail.com](mailto:kvgpedo@gmail.com), website : [kvgdentalcollege.org](http://kvgdentalcollege.org)**

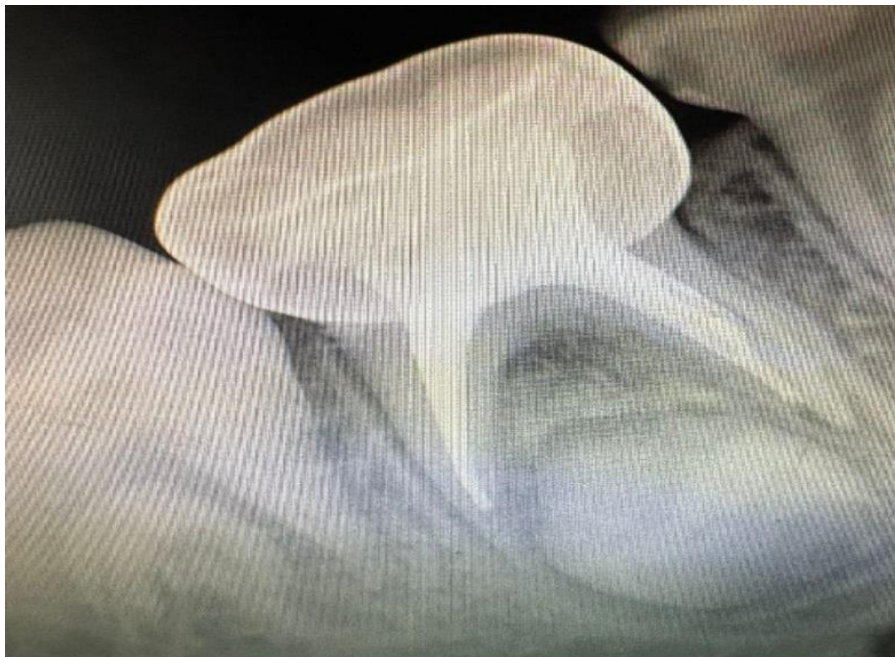17. Name: Mhd Shayan

Age:5

Gender: male

Diagnosis: Chronic irreversible pulpitis irt 85

Treatment plan: Pulpectomy irt 85 followed by crown



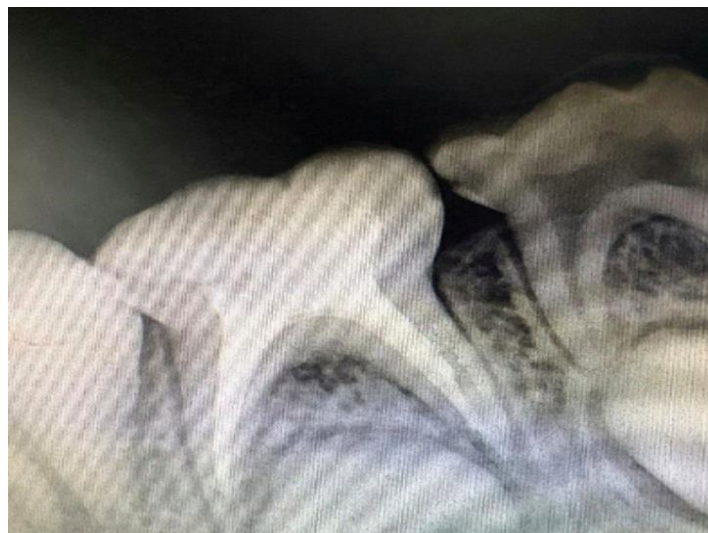18. Name: Himan Khanna

Age:7

Gender: male

Diagnosis: Chronic irreversible pulpitis irt 75

Treatment plan: Pulpectomy irt 75 followed by crown





DEPARTMENT OF PEDODONTICS AND PREVENTIVE DENTISTRY

KVG Dental College and Hospital

Kurunjibagh, Sullia- 574327, Karnataka, India

Phone :08257- 233148, 230608, 231089, Extn: 1211, Fax : 08257-230148

Email –[kvgpedo@gmail.com](mailto:kvgpedo@gmail.com), website : [kvgdentalcollege.org](http://kvgdentalcollege.org)

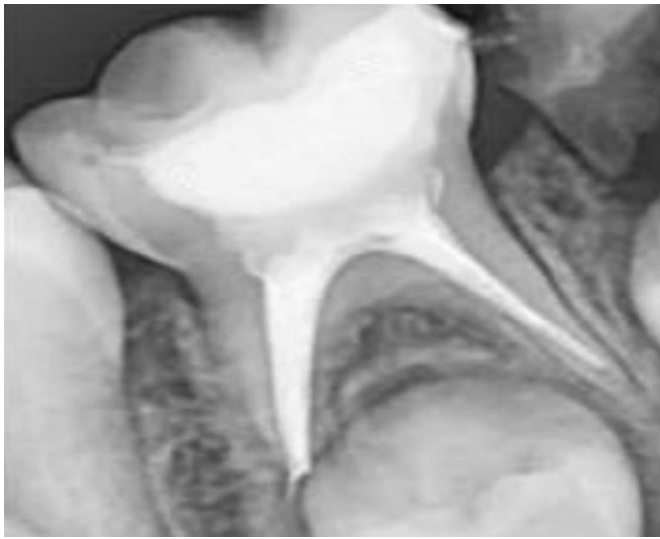19. Name: Lihal

Age:4

Gender: male

Diagnosis: Chronic irreversible pulpitis irt 75

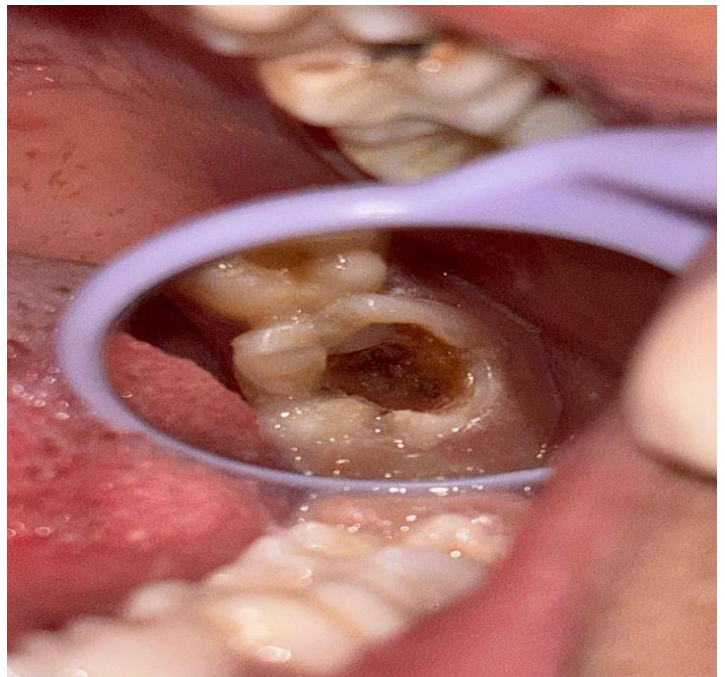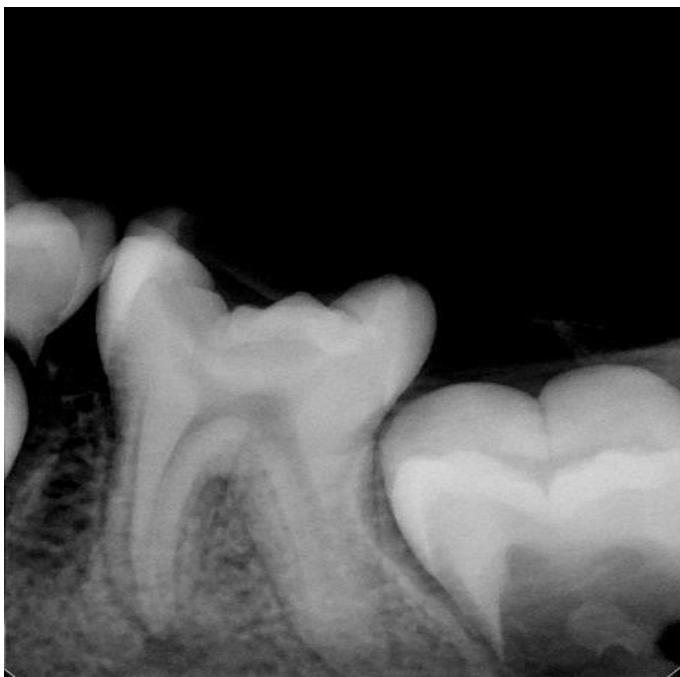Treatment plan: Pulpectomy irt 75 followed by crown

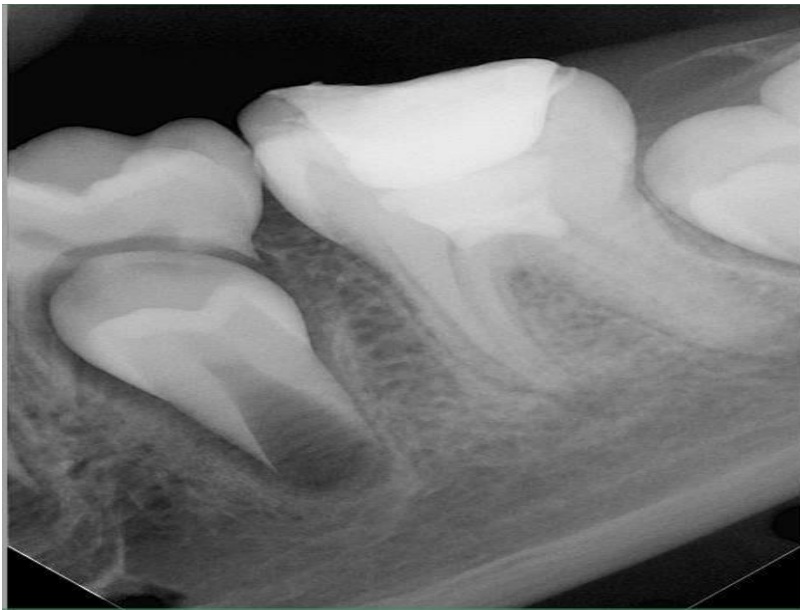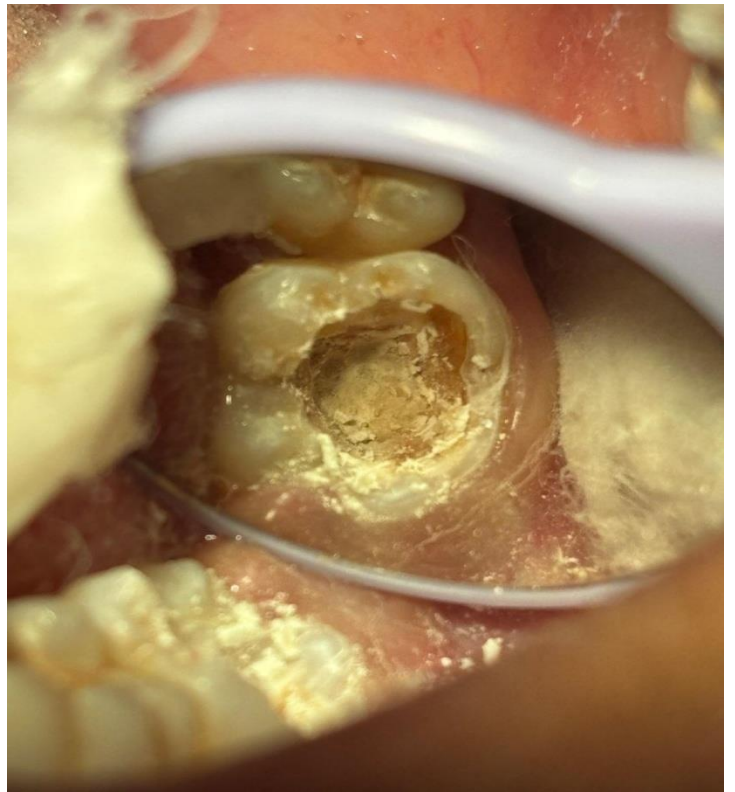

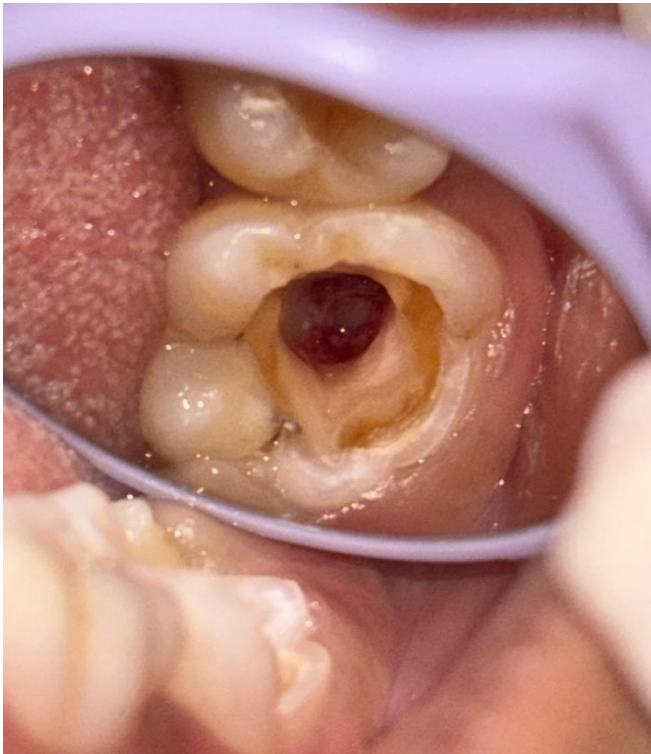
20.name: hastha rai ,

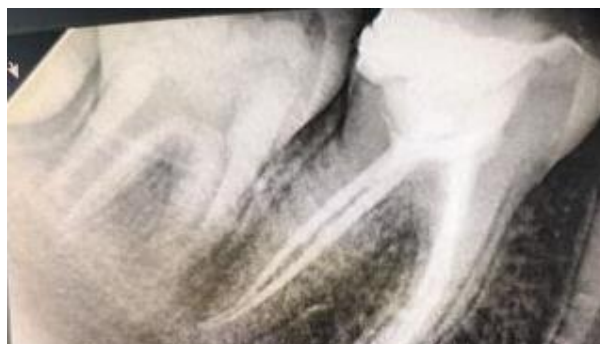diagnosis : irreversible pulpitis with periapical lesion with cvek stage IV root development

treatment done : apexogenesis irt 36





21. Name: Adithya  
Age: 11 year  
Gender: Male  
Diagnosis: Irreversible pulpitis 36 tooth  
Treatment done: RCT 36





DEPARTMENT OF PEDODONTICS AND PREVENTIVE DENTISTRY

KVG Dental College and Hospital

Kurunjibagh, Sullia- 574327, Karnataka, India

Phone :08257- 233148, 230608, 231089, Extn: 1211, Fax : 08257-230148

Email -[kvgedo@gmail.com](mailto:kvgedo@gmail.com), website : [kvgdentalcollege.org](http://kvgdentalcollege.org)

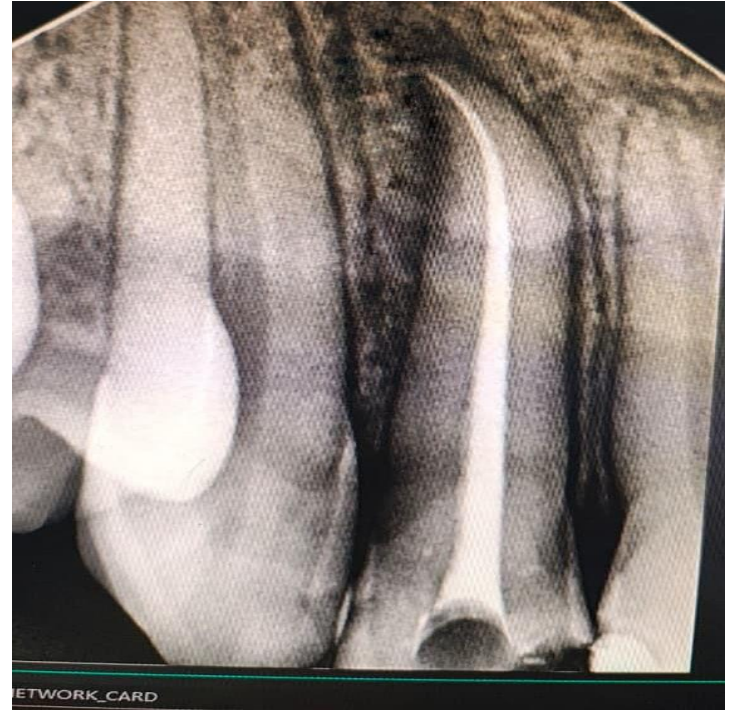
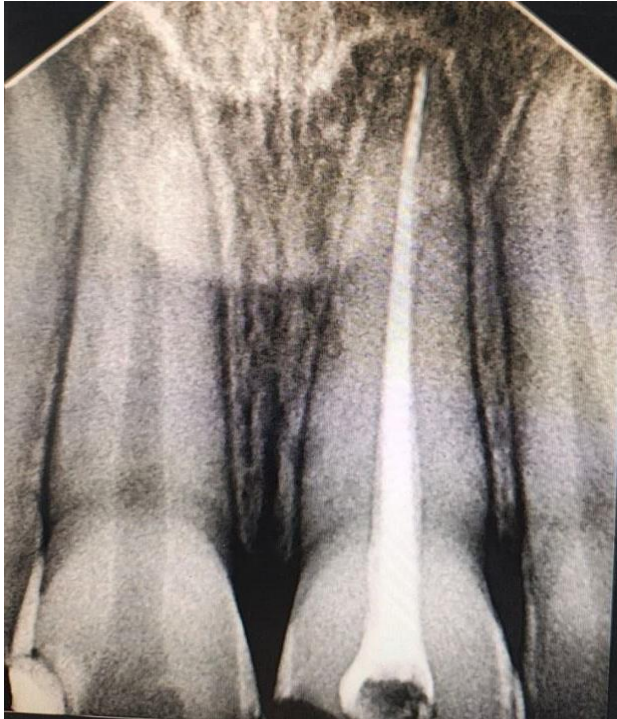22. Name: Majidha

Age: 13 year girl

Gender: Female

Diagnosis: Pulpal necrosis 21, 12

Treatment done: RCT irt 21,12

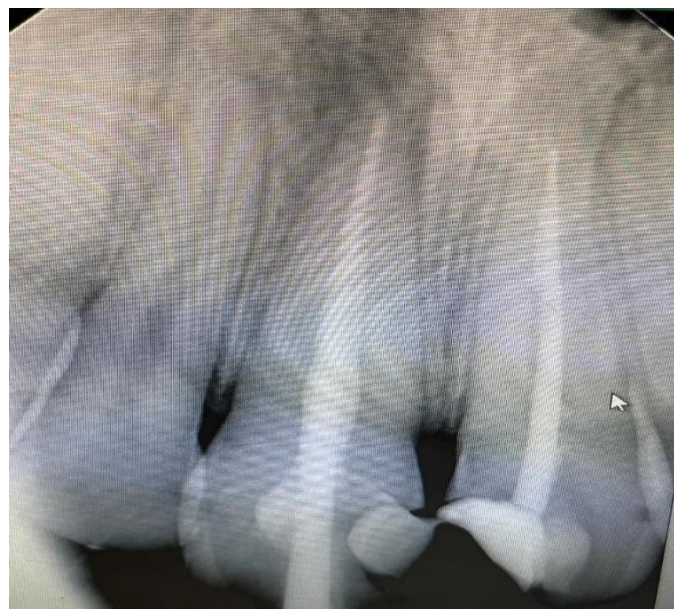
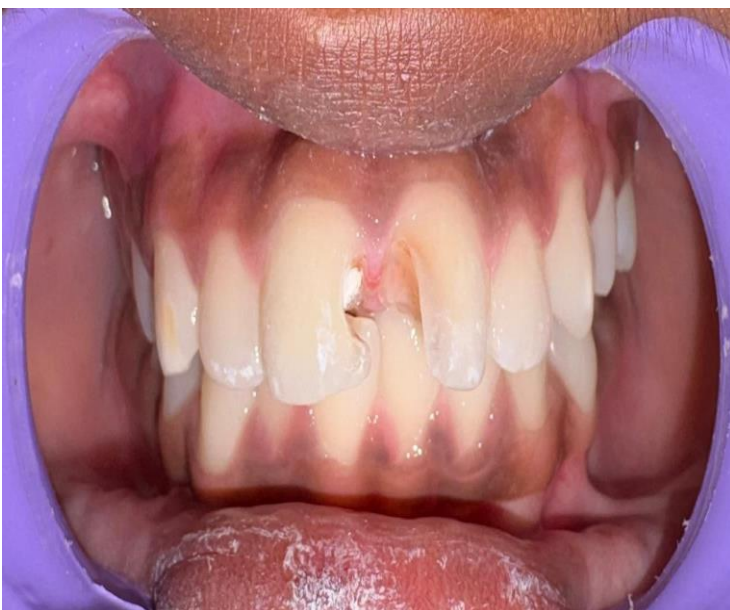
23. Name - Kumuda

Age- 11 yrs

Diagnosis- non vital teeth irt 11

Treatment- Root canal treatment irt 11





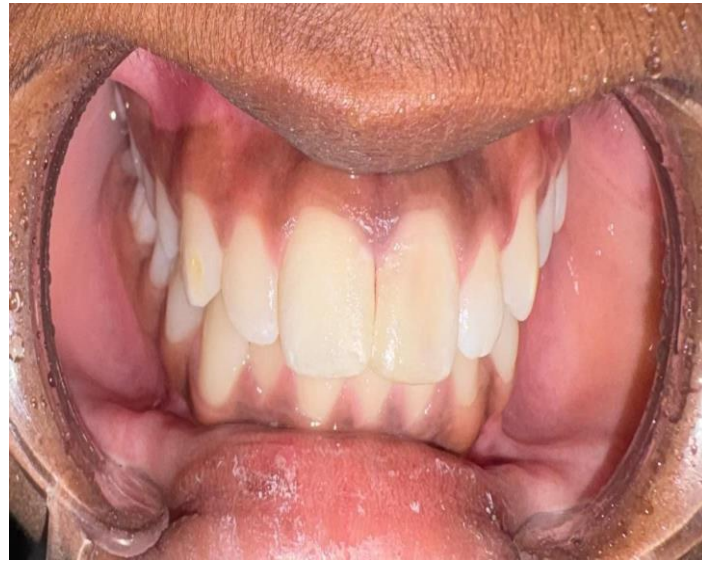DEPARTMENT OF PEDODONTICS AND PREVENTIVE DENTISTRY

KVG Dental College and Hospital

Kurunjibagh, Sullia- 574327, Karnataka, India

Phone :08257- 233148, 230608, 231089, Extn: 1211, Fax : 08257-230148

Email -[kvgpedo@gmail.com](mailto:kvgpedo@gmail.com), website : [kvgdentalcollege.org](http://kvgdentalcollege.org)

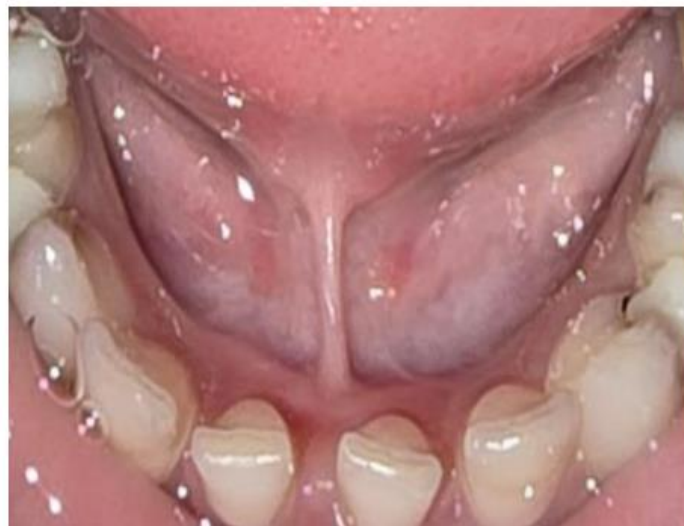
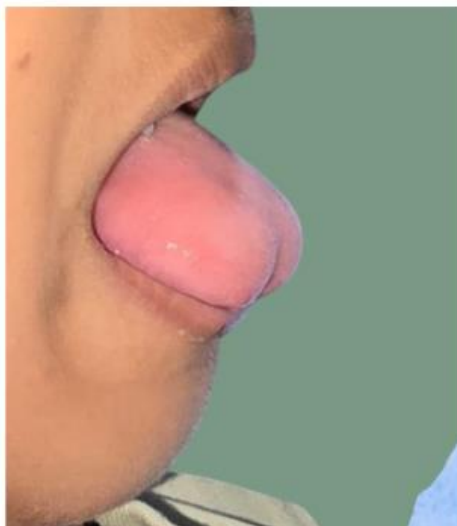
#### 24. MANAGEMENT OF ANKYLOGLOSSIA USING DIODE LASER

Name of the child: Diyan

Age: 6 years

Gender: Male



PRE-OPERATIVE IMAGES SHOWING TONGUE  
PROTRUSION AND FRENAL ATTACHMENT



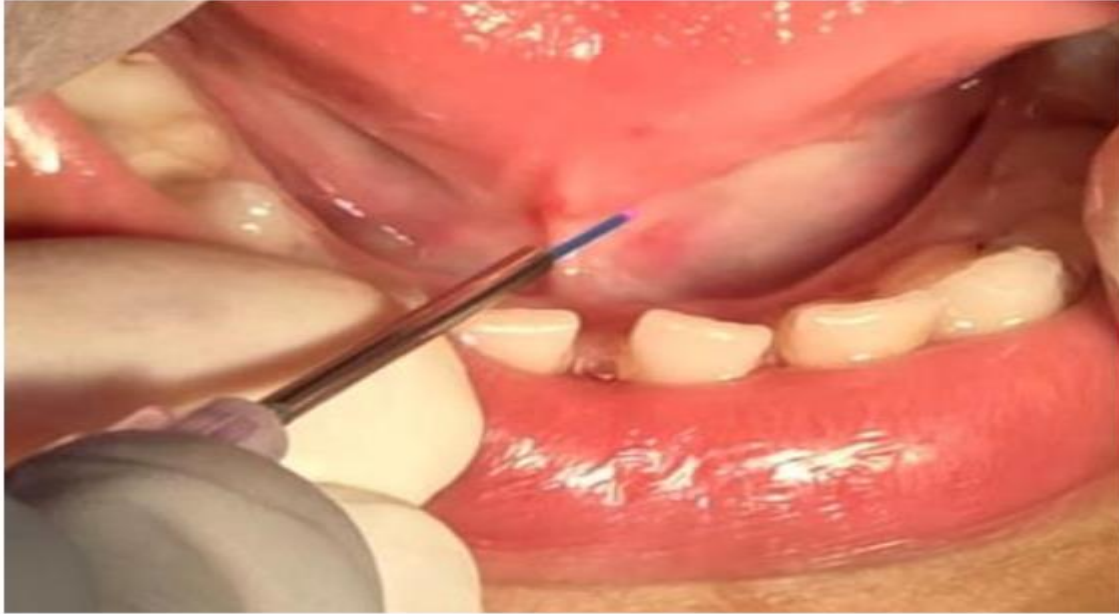DEPARTMENT OF PEDODONTICS AND PREVENTIVE DENTISTRY

KVG Dental College and Hospital

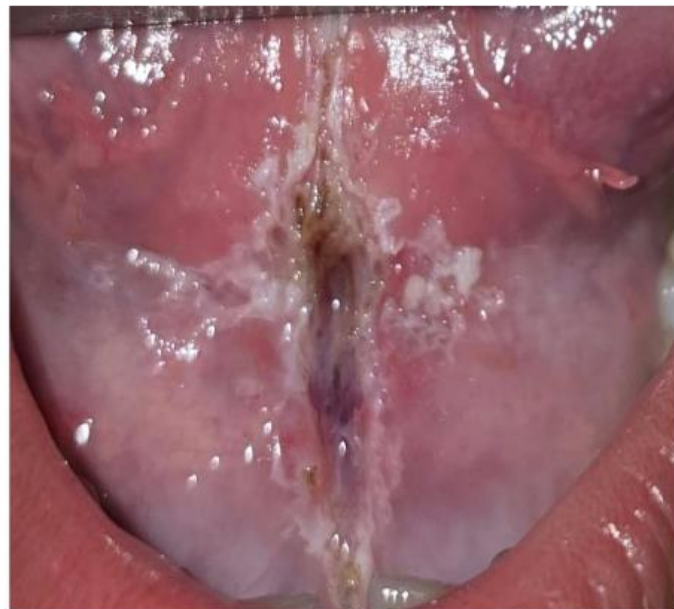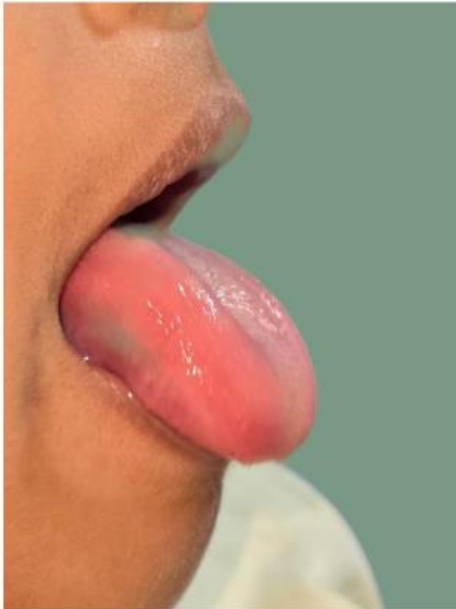Kurunjibagh, Sullia- 574327, Karnataka, India

Phone :08257- 233148, 230608, 231089, Extn: 1211, Fax : 08257-230148

Email –[kvgpedo@gmail.com](mailto:kvgpedo@gmail.com), website : [kvgdentalcollege.org](http://kvgdentalcollege.org)



INTRA-OPERATIVE IMAGE SHOWING USAGE OF DIODE LASER IN CONTACT MODE TO RELIEVE FRENAL ATTACHMENT



POST-OPERATIVE IMAGES SHOWING TONGUE PROTRUSION AND RELIEVED FRENAL ATTACHMENT



DEPARTMENT OF PEDODONTICS AND PREVENTIVE DENTISTRY

KVG Dental College and Hospital

Kurunjibagh, Sullia- 574327, Karnataka, India

Phone :08257- 233148, 230608, 231089, Extn: 1211, Fax : 08257-230148

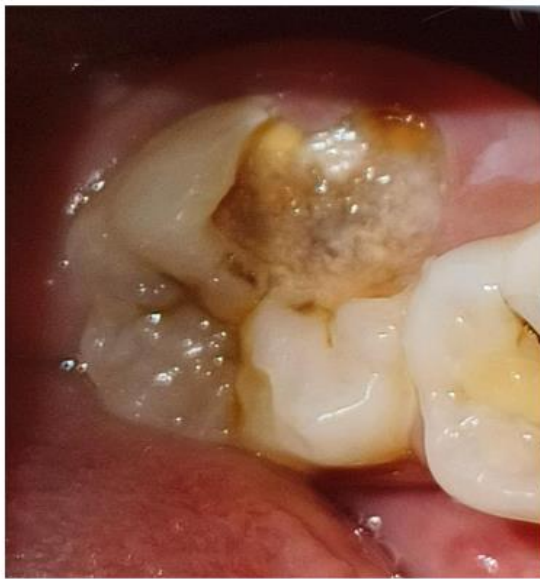Email -[kvgpedo@gmail.com](mailto:kvgpedo@gmail.com), website : [kvgdentalcollege.org](http://kvgdentalcollege.org)

## 25. MANAGEMENT OF NON-VITAL IMMATURE PERMANENT TEETH WITH OPEN APEX USING MTA APEXIFICATION

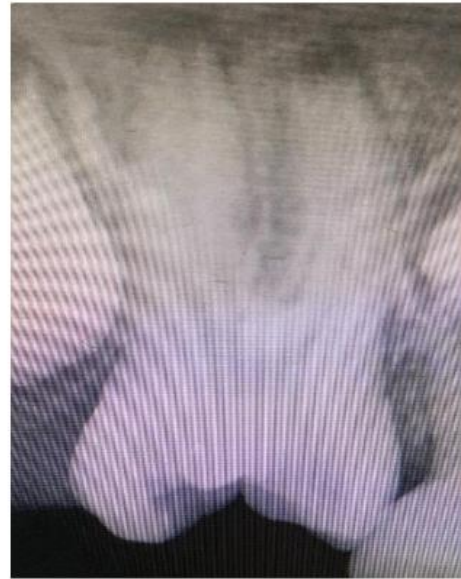Name Of The Child: Fathimath Fahama

Age: 11 Years

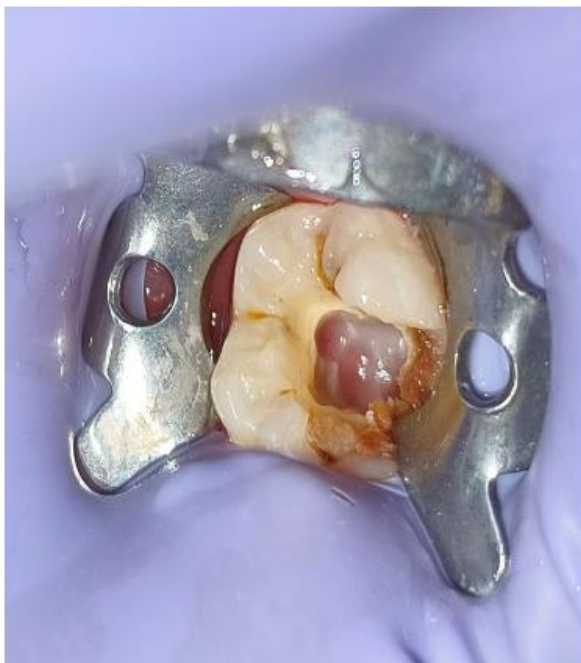Gender: Female



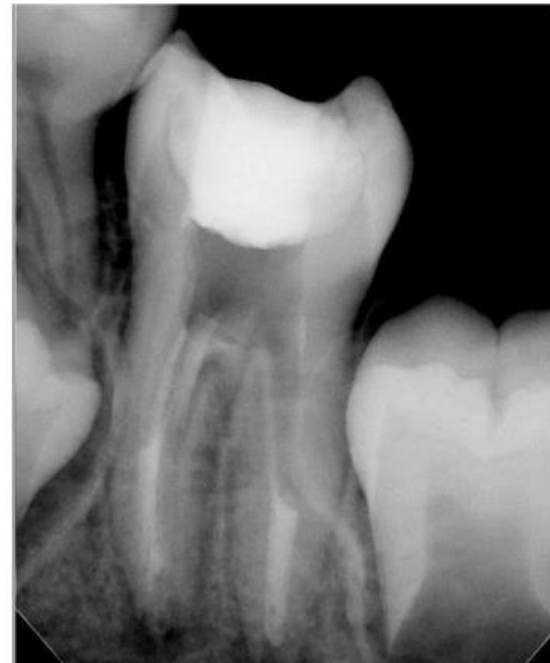INTRAORAL IMAGE TAKEN IRT 36



IOPAR TAKEN IRT 36



INTRAORAL IMAGE TAKEN AFTER ACCESS  
OPENING



IOPAR TAKEN IRT 36 AFTER  
PLACEMENT OF MTA PLUG



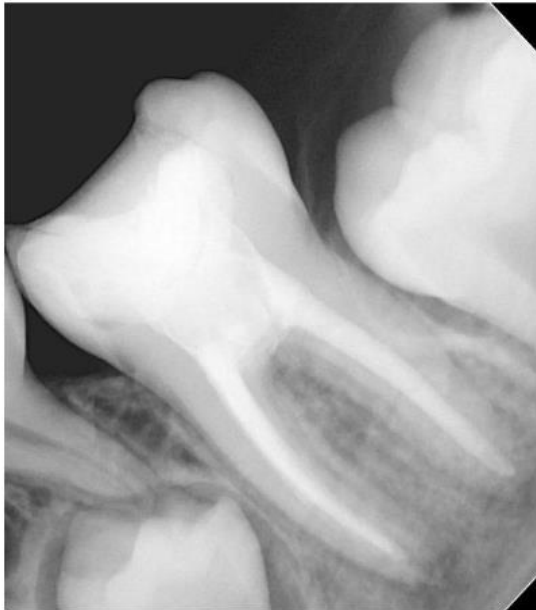DEPARTMENT OF PEDODONTICS AND PREVENTIVE DENTISTRY

KVG Dental College and Hospital

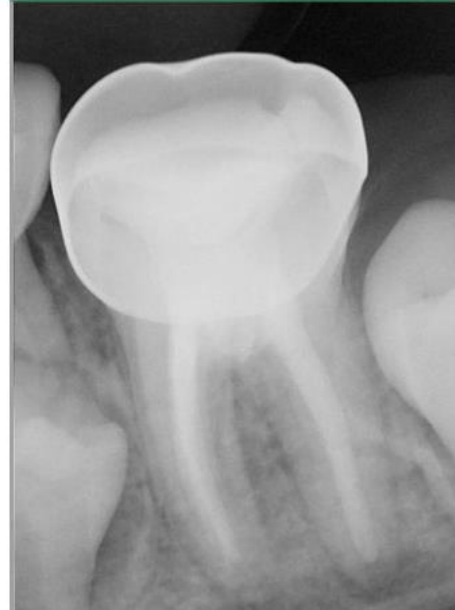Kurunjibagh, Sullia- 574327, Karnataka, India

Phone :08257- 233148, 230608, 231089, Extn: 1211, Fax : 08257-230148

Email - [kvgpedo@gmail.com](mailto:kvgpedo@gmail.com), website : [kvgdentalcollege.org](http://kvgdentalcollege.org)



OBTURATION DONE IRT 36



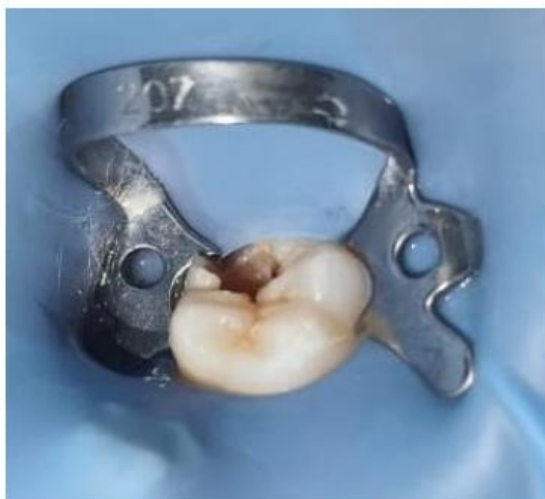IOPAR TAKEN IRT 36 AFTER SSC DELIVERY  
AFTER 1 MONTH FOLLOWUP

## 26. MANAGEMENT OF VITAL IMMATURE PERMANENT TOOTH WITH OPEN APEX BY METAPEX APEXOGENESIS

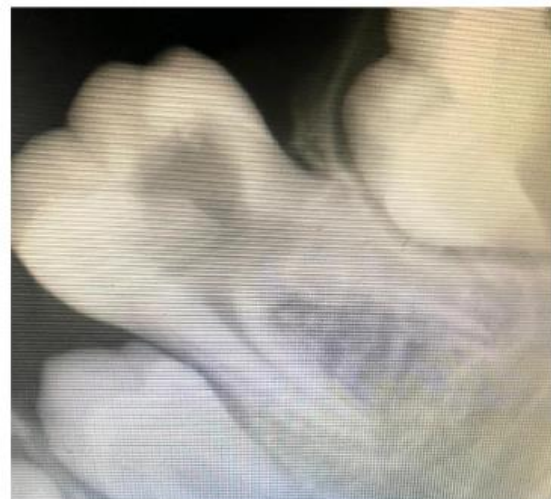Name of the child: Md.Shayan

Age : 8 years

Gender: Male



PRE-OP PICTURE AFTER RUBBER DAM ISOLATION AND PRIOR TO



PRE-OP IOPAR IRT 36



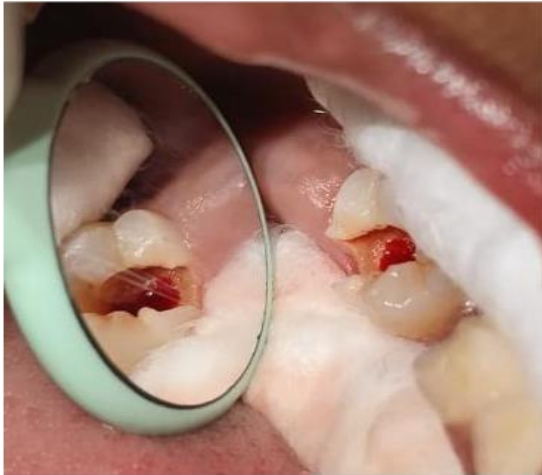DEPARTMENT OF PEDODONTICS AND PREVENTIVE DENTISTRY

KVG Dental College and Hospital

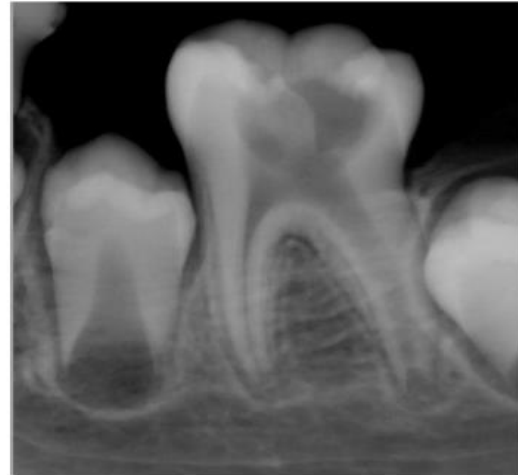
Kurunjibagh, Sullia- 574327, Karnataka, India

Phone :08257- 233148, 230608, 231089, Extn: 1211, Fax : 08257-230148

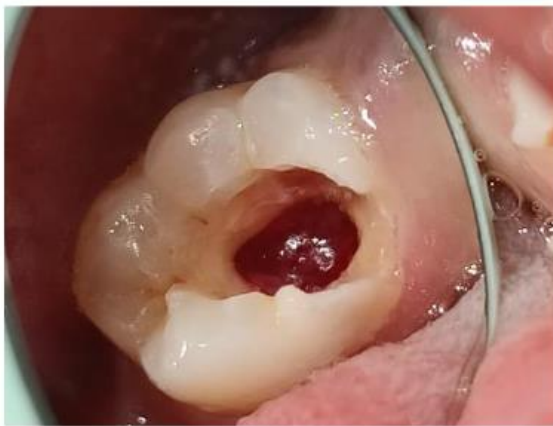Email –[kvgedo@gmail.com](mailto:kvgedo@gmail.com), website : [kvgdentalcollege.org](http://kvgdentalcollege.org)



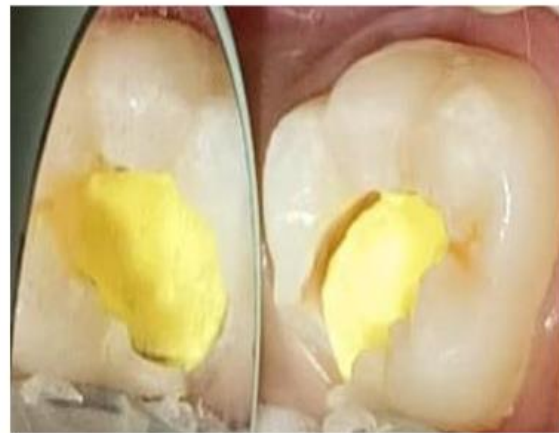AFTER ACCESS OPENING- VITALITY WAS ENSURED BASED ON THE COLOR OF BLEEDING



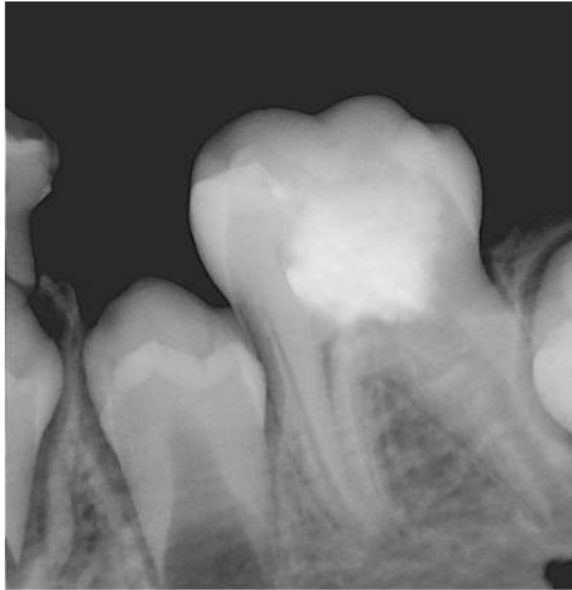IOPAR POST ACCESS OPENING



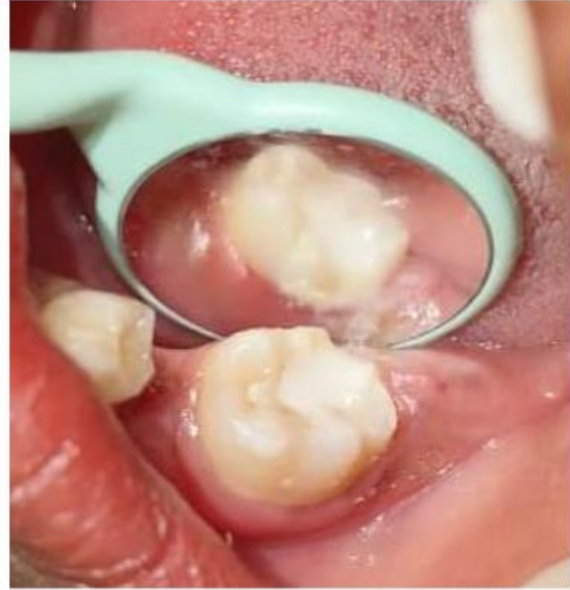INTRAORAL IMAGE AFTER THE SESSATION OF BLEEDING POST PULPOTOMY



INTRAORAL PICTURE AFTER THE PLACEMENT OF METAPEX



IOPAR AFTER THE PLACEMENT OF  
METAPEX FOLLOWED BY CORONAL SEAL



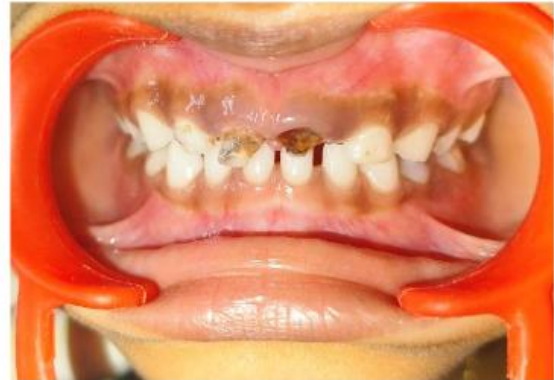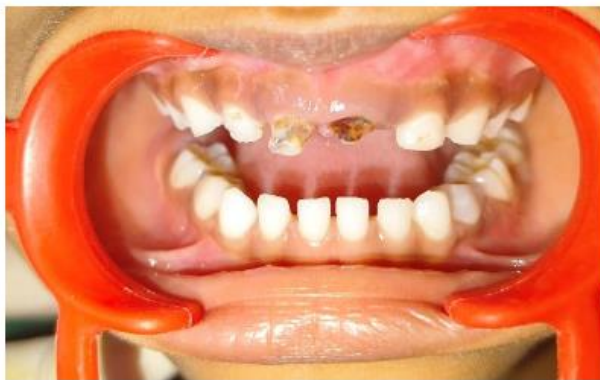POST-OP IMAGE AFTER GIC  
RESTORATION

## 27. ANTERIOR REHABILITATION OF STAGE -III EARLY CHILDHOOD CARIES USING STRIP CROWNS

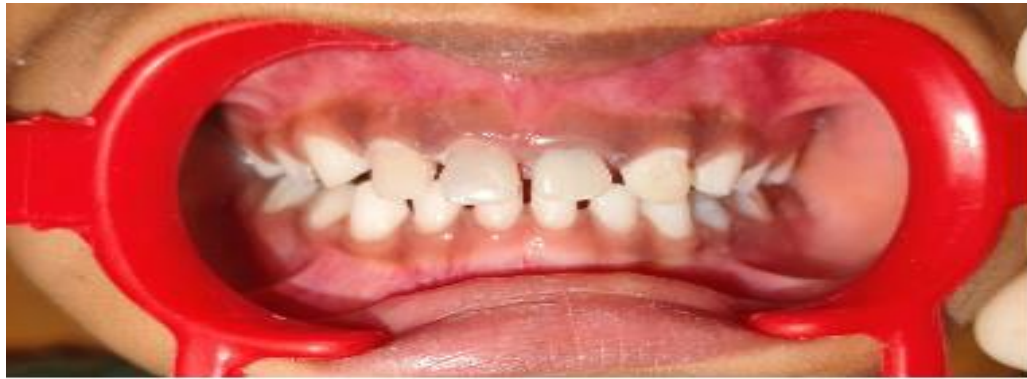Name of the child: Bathul

Age: 5 years

Gender: Female



PRE-OPERATIVE INTRAORAL IMAGES AND IOPAR IRT  
51, 61



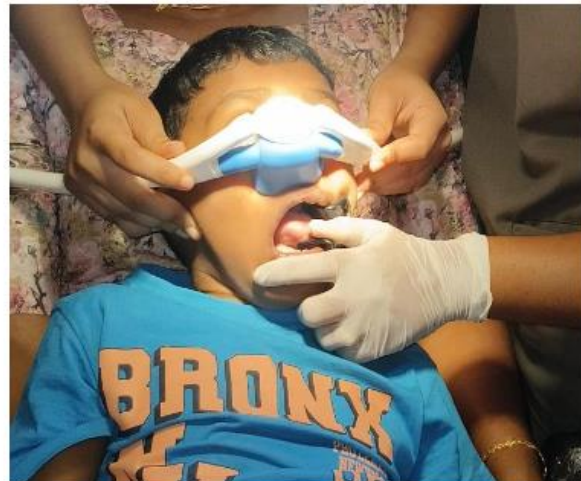POST-OPERATIVE INTRAORAL IMAGES AFTER SDF+KI APPLICATION AND COMPOSITE STRIP CROWN DELIVERY

28. ORAL REHABILITATION OF CHILD WITH AUTISM, ADHD AND EPILEPSY UNDER NITROUS OXIDE CONSCIOUS SEDATION

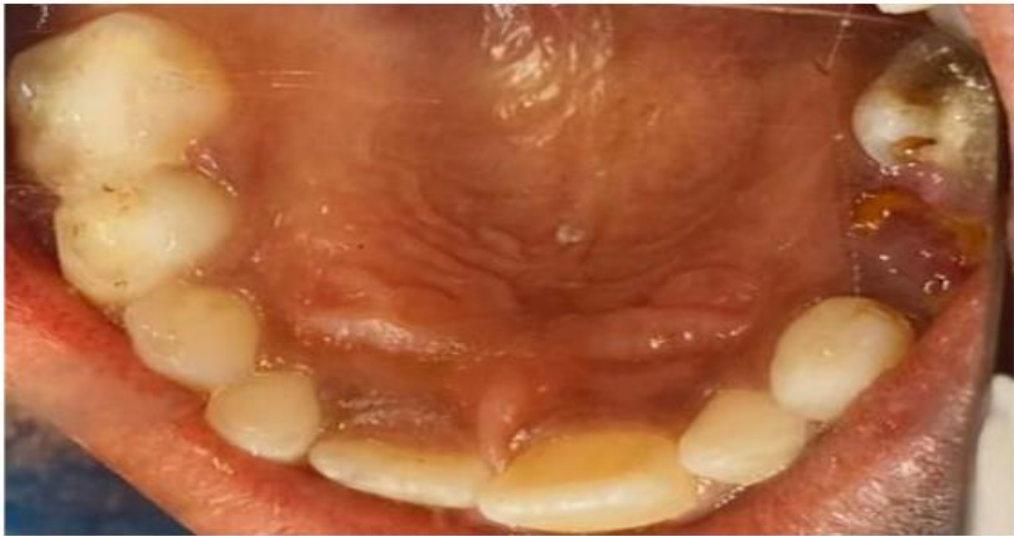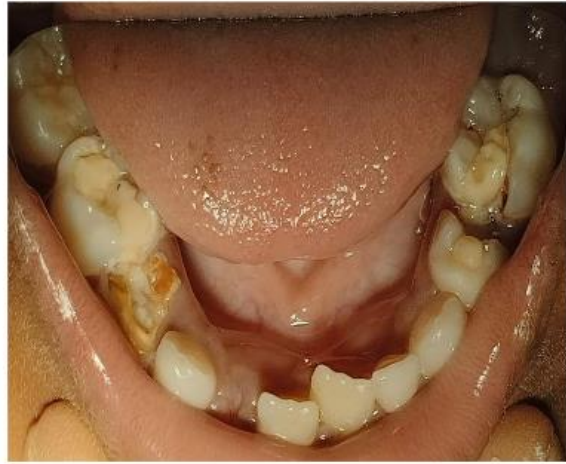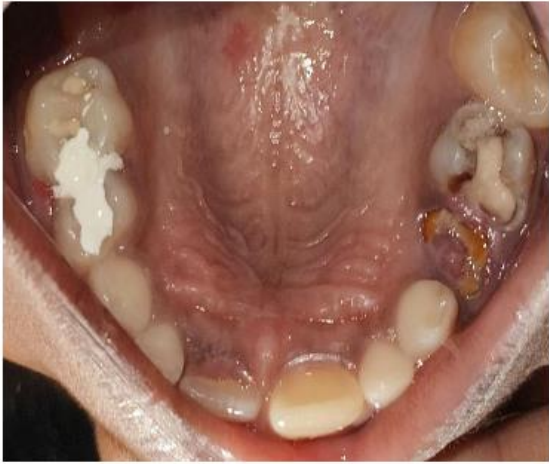Name of the child: David Justin

Age: 7 years

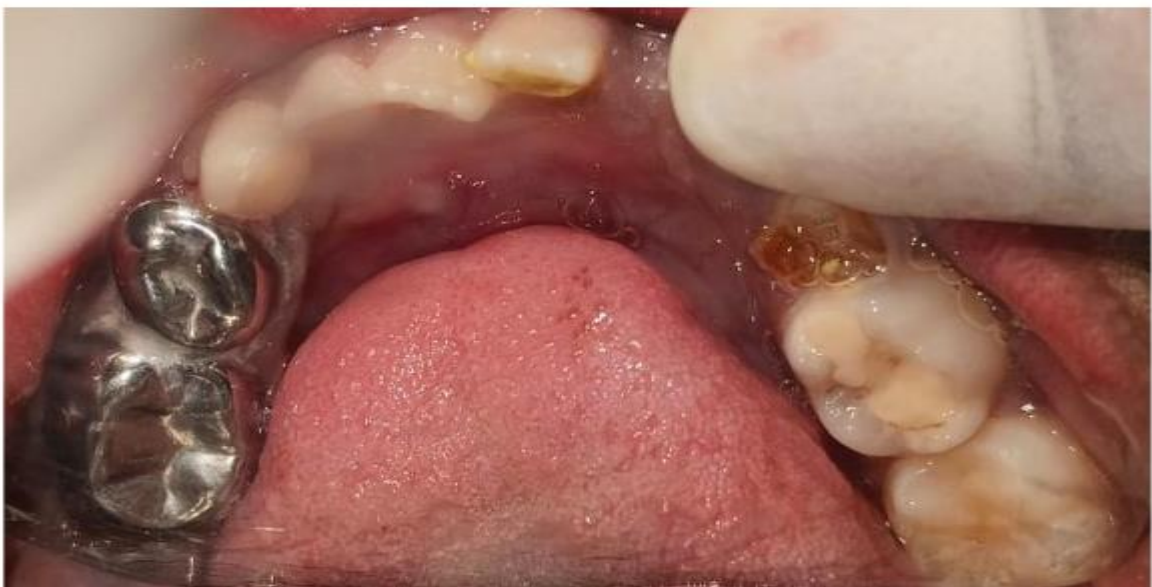Gender: Male



PRE-OPERATIVE AND INTRA-OPERATIVE, INTRAORAL AND EXTRAORAL PICTURES



POST OPERATIVE, INTRAORAL IMAGES





DEPARTMENT OF PEDODONTICS AND PREVENTIVE DENTISTRY

KVG Dental College and Hospital

Kurunjibagh, Sullia- 574327, Karnataka, India

Phone :08257- 233148, 230608, 231089, Extn: 1211, Fax : 08257-230148

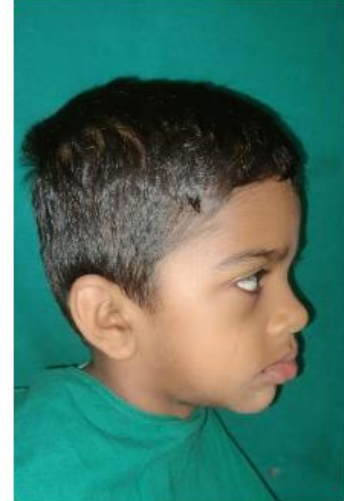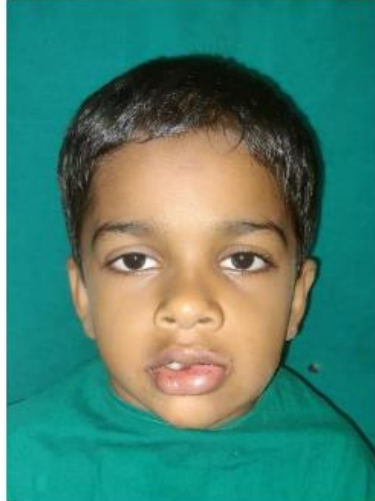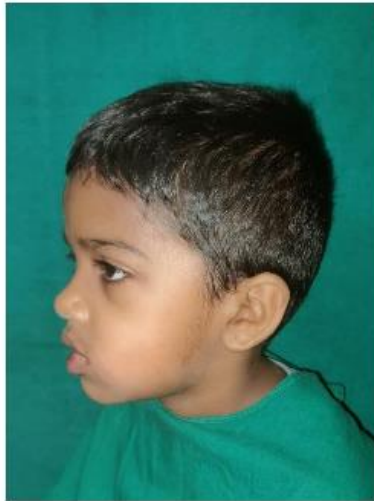Email –[kvgpedo@gmail.com](mailto:kvgpedo@gmail.com), website : [kvgdentalcollege.org](http://kvgdentalcollege.org)

## 29. MANAGEMENT OF DENTOALVEOLAR FRACTURE UNDER CONSCIOUS SEDATION

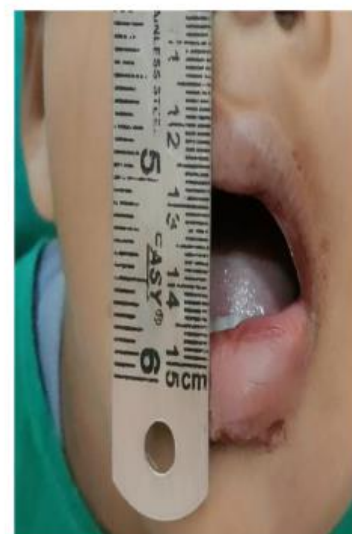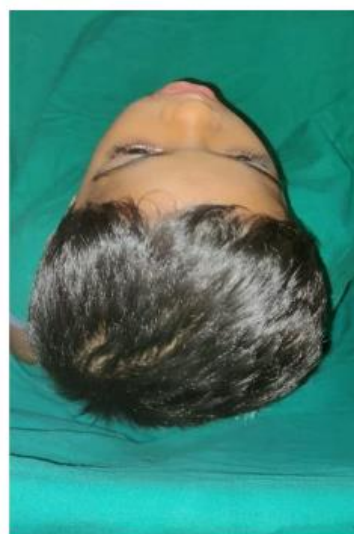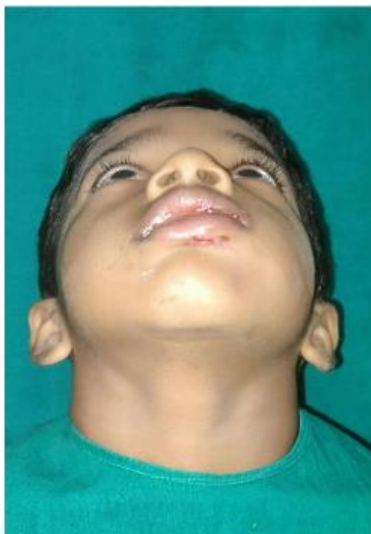Name of the child: Abhinav

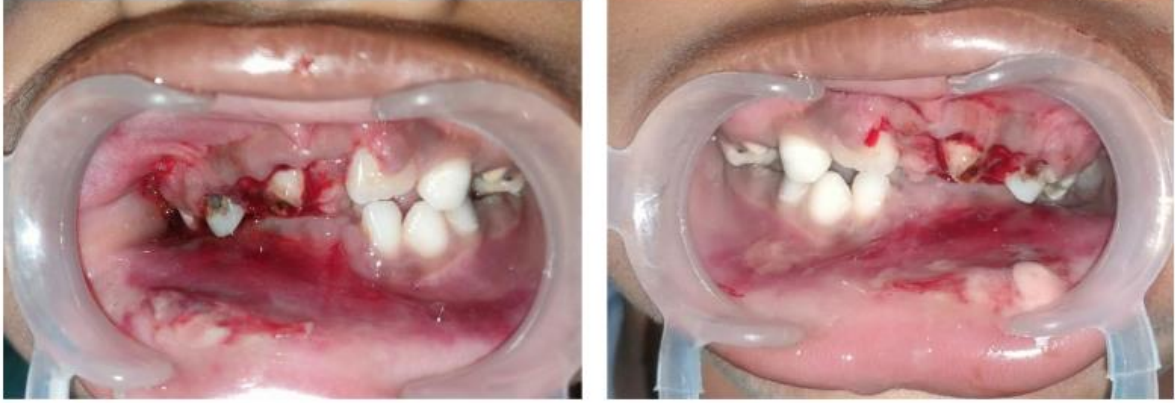Age: 6 years

Gender: Male

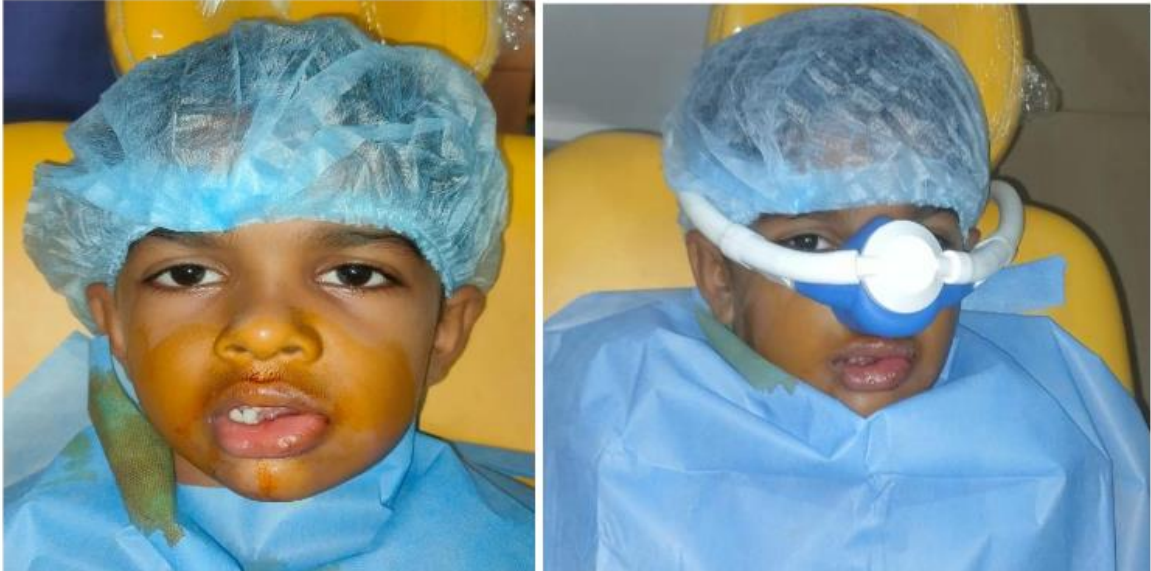

PRE-OPERATIVE EXTRA ORAL IMAGES  
TAKEN BEFORE TREATMENT





PRE-OPERATIVE INTRA ORAL IMAGES  
TAKEN BEFORE TREATMENT



PRE-OPERATIVE EXTRA ORAL IMAGES TAKEN AFTER  
PAINTING AND CONSED ADMINISTRATION



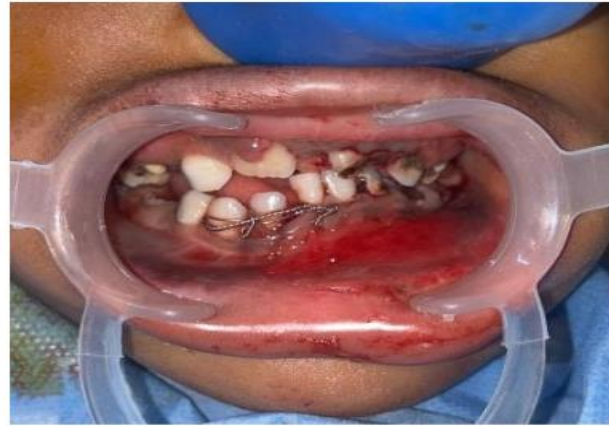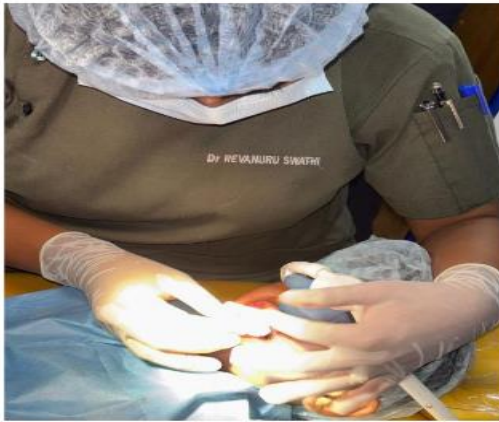DEPARTMENT OF PEDODONTICS AND PREVENTIVE DENTISTRY

KVG Dental College and Hospital

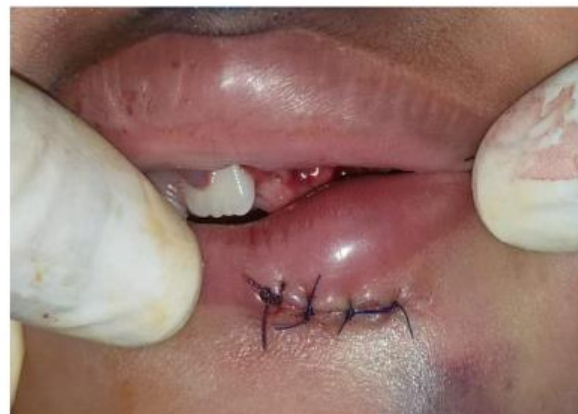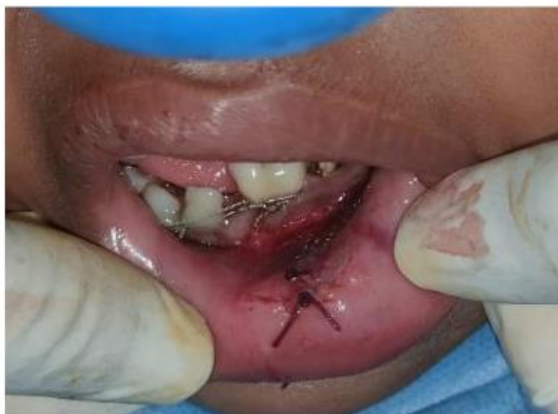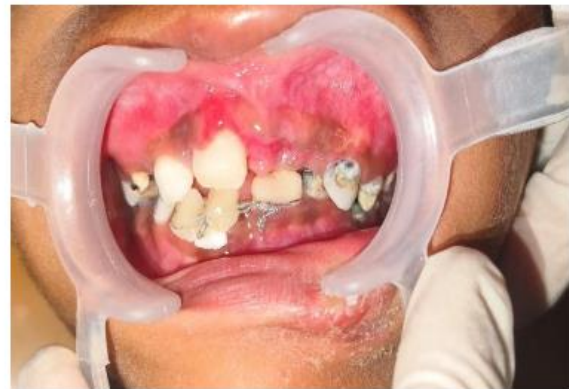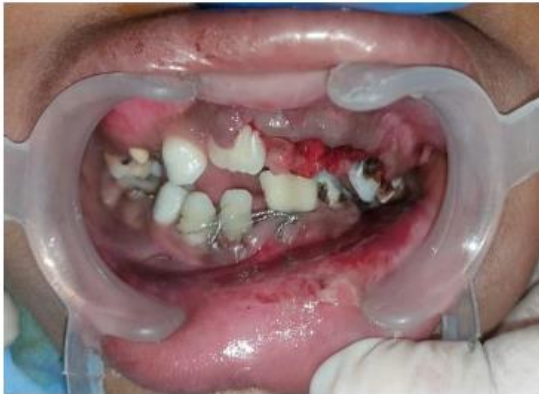Kurunjibagh, Sullia- 574327, Karnataka, India

Phone :08257- 233148, 230608, 231089, Extn: 1211, Fax : 08257-230148

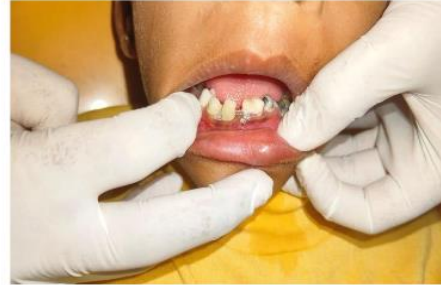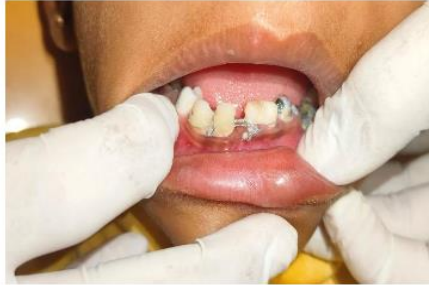Email –[kvgpedo@gmail.com](mailto:kvgpedo@gmail.com), website : [kvgdentalcollege.org](http://kvgdentalcollege.org)



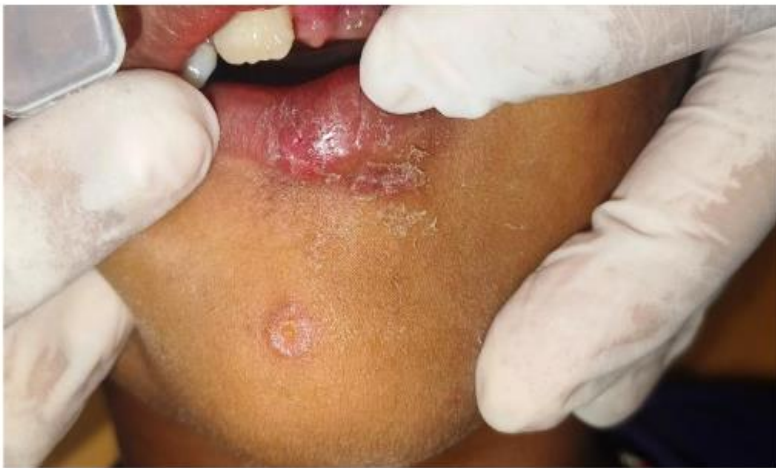INTRA-OPERATIVE IMAGES DURING  
EXTRACTION, AFTER SPLINTING

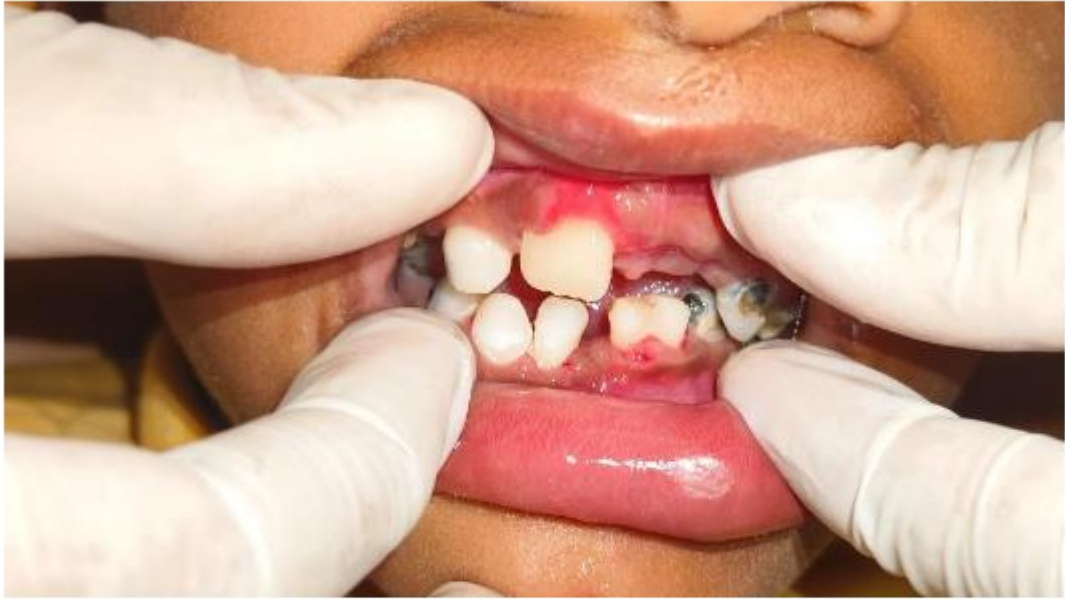

POST-OPERATIVE IMAGES AFTER  
EXTRAORAL AND INTRAORAL SUTURING

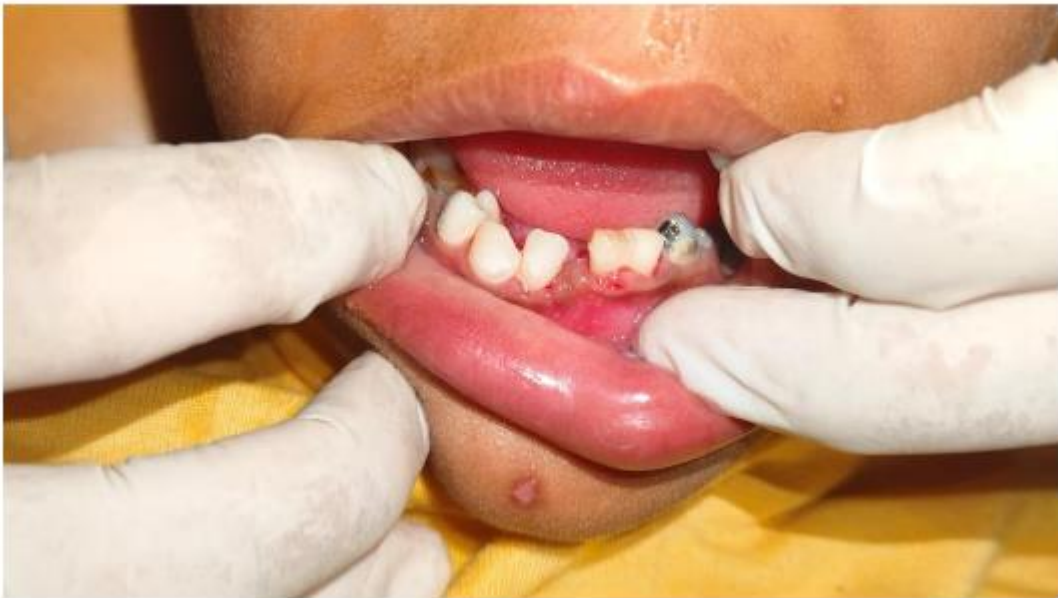

EXTRAORAL AND INTRAORAL IMAGES  
TAKEN 15 DAYS AFTER THE TREATMENT





INTRAORAL IMAGES TAKEN AFTER SPLINT AND BRIDLE WIRE REMOVAL -ONE MONTH FOLLOWUP





DEPARTMENT OF PEDODONTICS AND PREVENTIVE DENTISTRY

KVG Dental College and Hospital

Kurunjibagh, Sullia- 574327, Karnataka, India

Phone :08257- 233148, 230608, 231089, Extn: 1211, Fax : 08257-230148

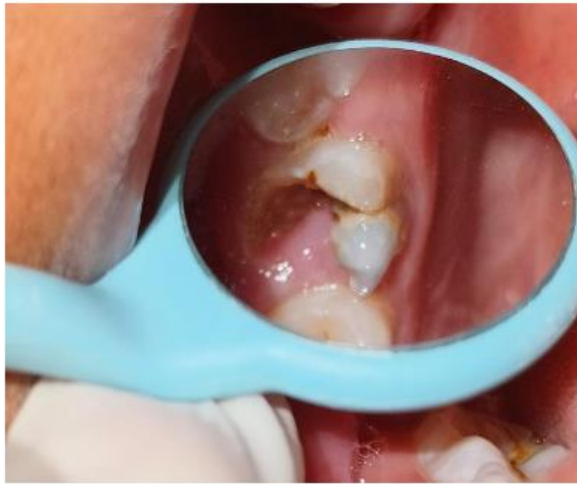Email -[kvgpedo@gmail.com](mailto:kvgpedo@gmail.com), website : [kvgdentalcollege.org](http://kvgdentalcollege.org)

### 30. MANAGEMENT OF GINGIVAL POLYP AND MUTILATED TOOTH

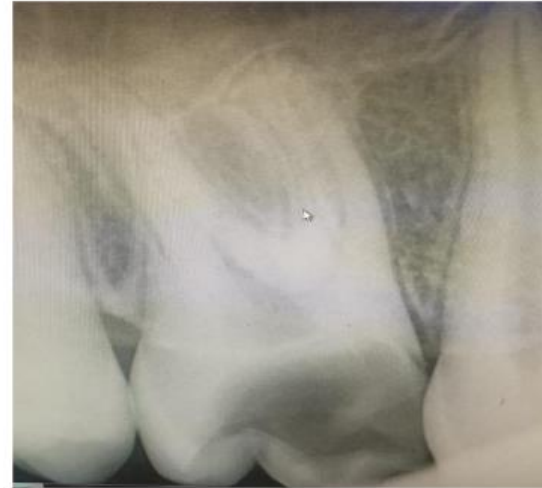Name of the child: Thwahir

Age: 13 years

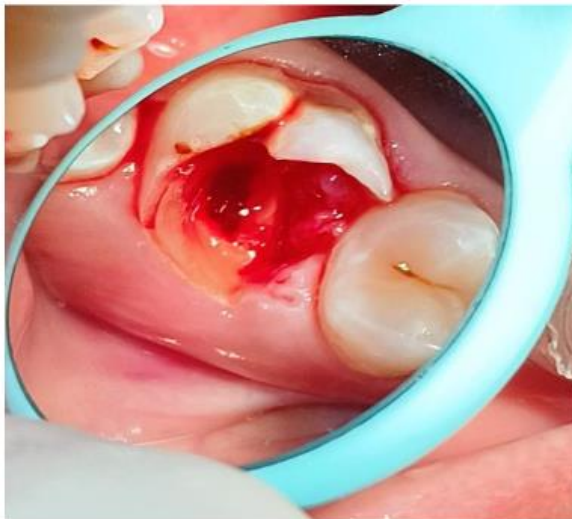Gender: Male



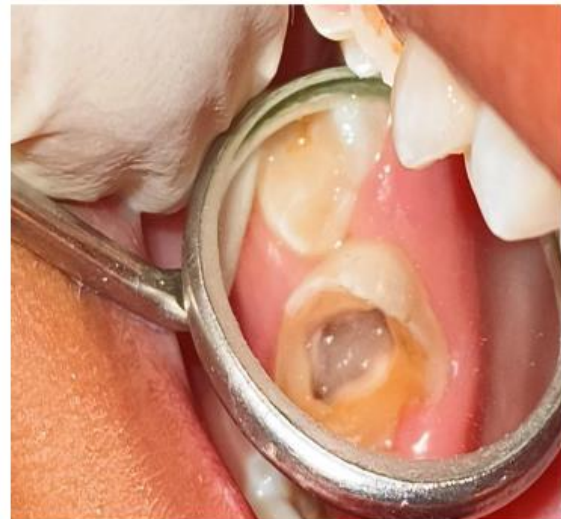PRE-OP INTRAORAL IMAGE SHOWING  
GINGIVAL POLYP IRT 16



IOPAR IRT 16



INTRA-ORAL IMAGE POST EXCISION OF  
GINGIVAL POLYP IRT 16



INTRA-ORAL IMAGE POST HEMORRHAGE  
CONTROL AND ACCESS OPENING IRT 16



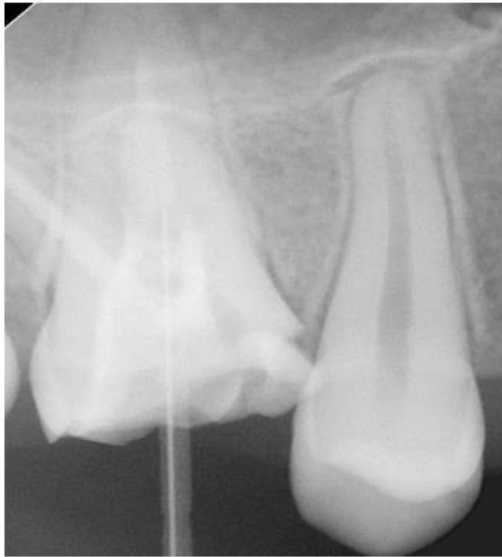**DEPARTMENT OF PEDODONTICS AND PREVENTIVE DENTISTRY**

**KVG Dental College and Hospital**

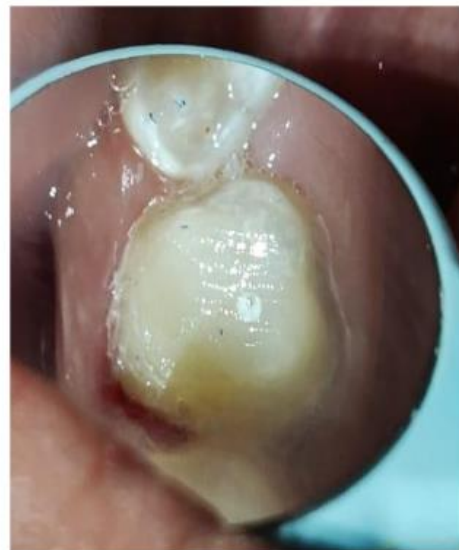
**Kurunjibagh, Sullia- 574327, Karnataka, India**

**Phone :08257- 233148, 230608, 231089, Extn: 1211, Fax : 08257-230148**

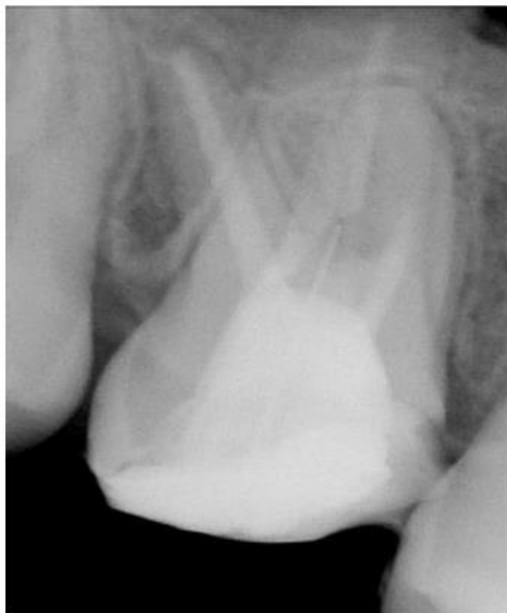**Email –[kvgpedo@gmail.com](mailto:kvgpedo@gmail.com), website : [kvgdentalcollege.org](http://kvgdentalcollege.org)**



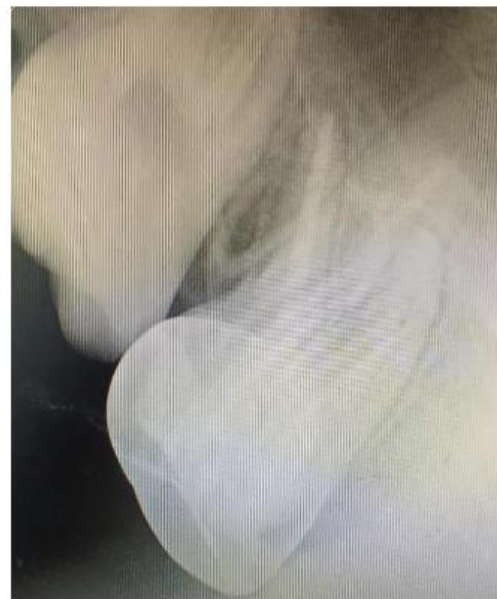
IOPAR IRT 16 AFTER STABILIZING  
FIBRE POST



INTRA-ORAL IMAGE TAKEN IRT 16  
AFTER POST AND CORE BUILDUP



IOPAR IRT 16 AFTER POST AND CORE  
PLACEMENT



IOPAR IRT 16 ONE MONTH AFTER SSC  
DELIVERY



DEPARTMENT OF PEDODONTICS AND PREVENTIVE DENTISTRY

KVG Dental College and Hospital

Kurunjibagh, Sullia- 574327, Karnataka, India

Phone : 08257- 233148, 230608, 231089, Extn: 1211, Fax : 08257-230148

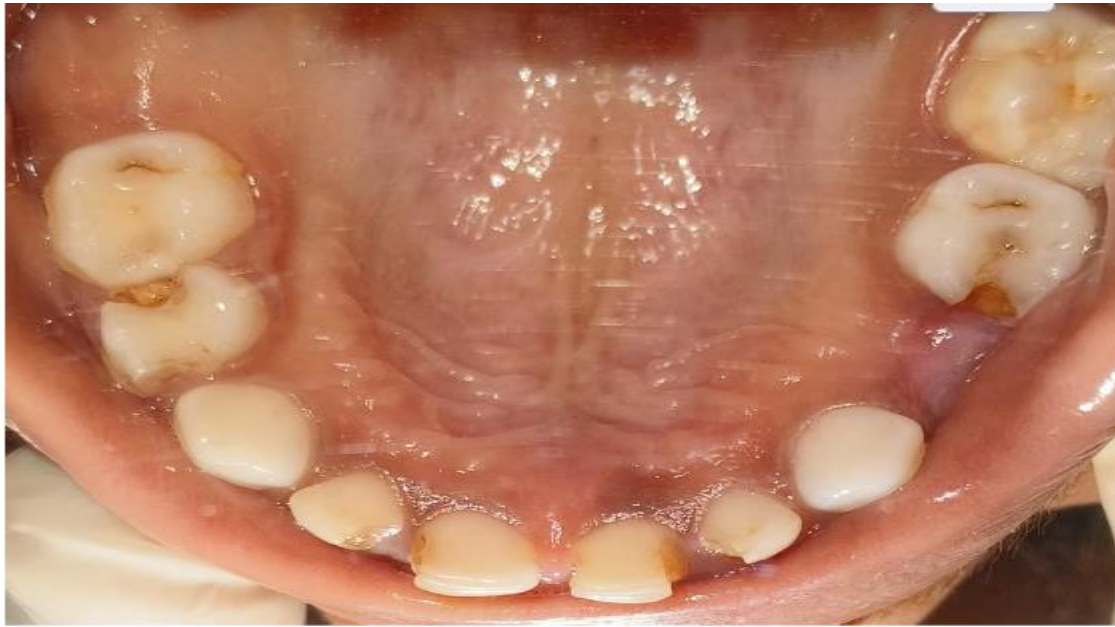Email – [kvgpedo@gmail.com](mailto:kvgpedo@gmail.com), website : [kvgdentalcollege.org](http://kvgdentalcollege.org)

### 31. FULL MOUTH REHABILITATION OF A CHILD WITH EARLY CHILDHOOD CARIES

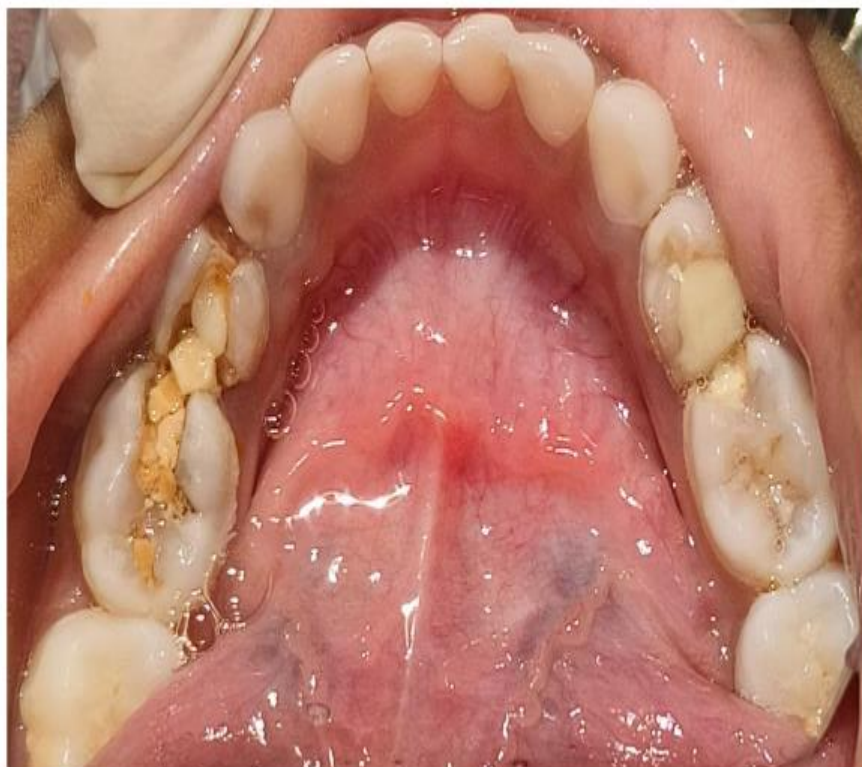Name: Shaika Riza

Age: 6 years

Sex: Female



PRE-OPERATIVE UPPER AND LOWER INTRA-ORAL IMAGES





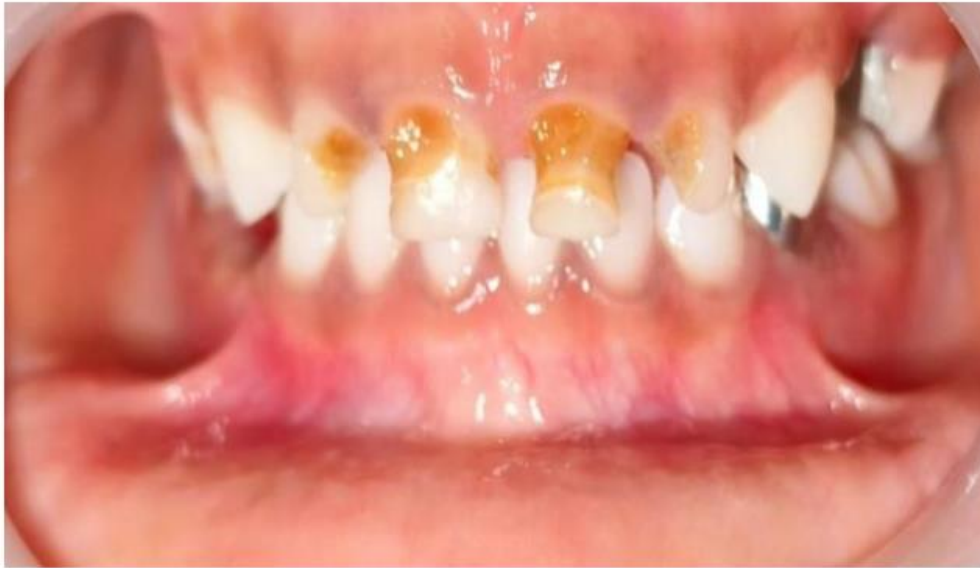DEPARTMENT OF PEDODONTICS AND PREVENTIVE DENTISTRY

KVG Dental College and Hospital

Kurunjibagh, Sullia- 574327, Karnataka, India

Phone :08257- 233148, 230608, 231089, Extn: 1211, Fax : 08257-230148

Email –[kvgpedo@gmail.com](mailto:kvgpedo@gmail.com), website : [kvgdentalcollege.org](http://kvgdentalcollege.org)



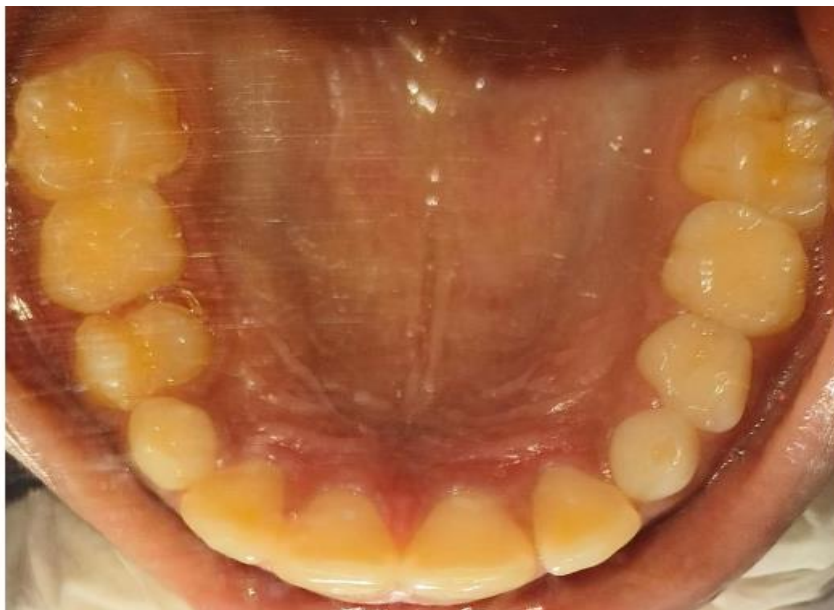PRE-OPERATIVE ANTERIOR INTRA-ORAL IMAGE

### 32. MANAGEMENT OF EDENTULOUS AREA IRT 84,85

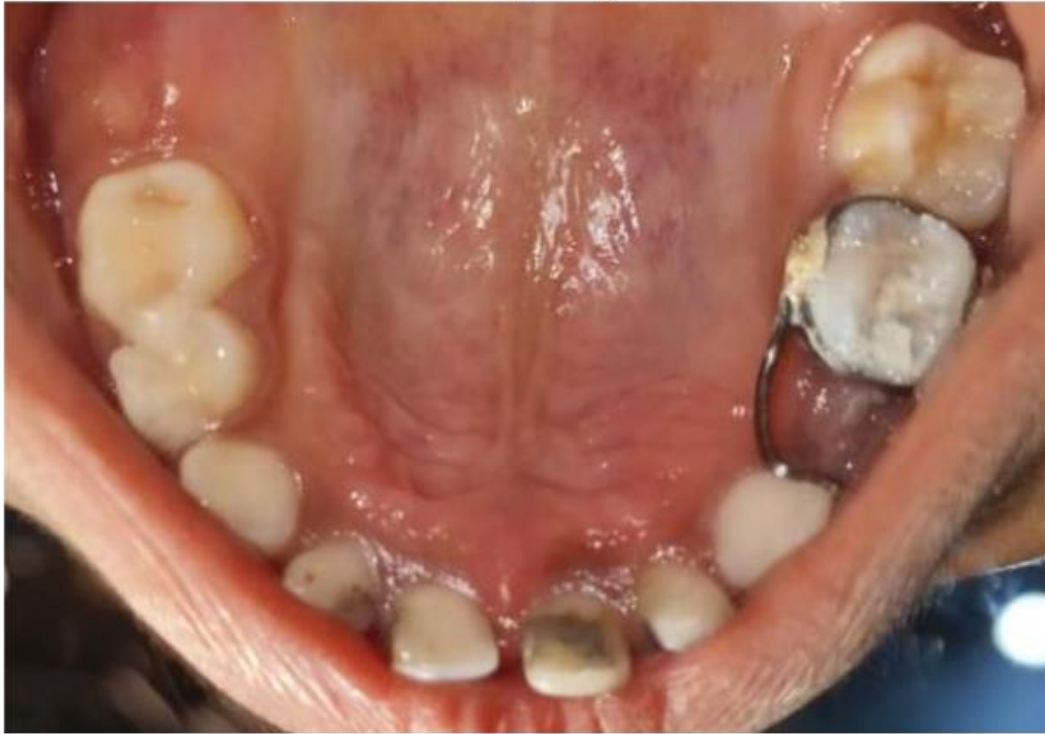Name : Hafeel

Age: 10 years

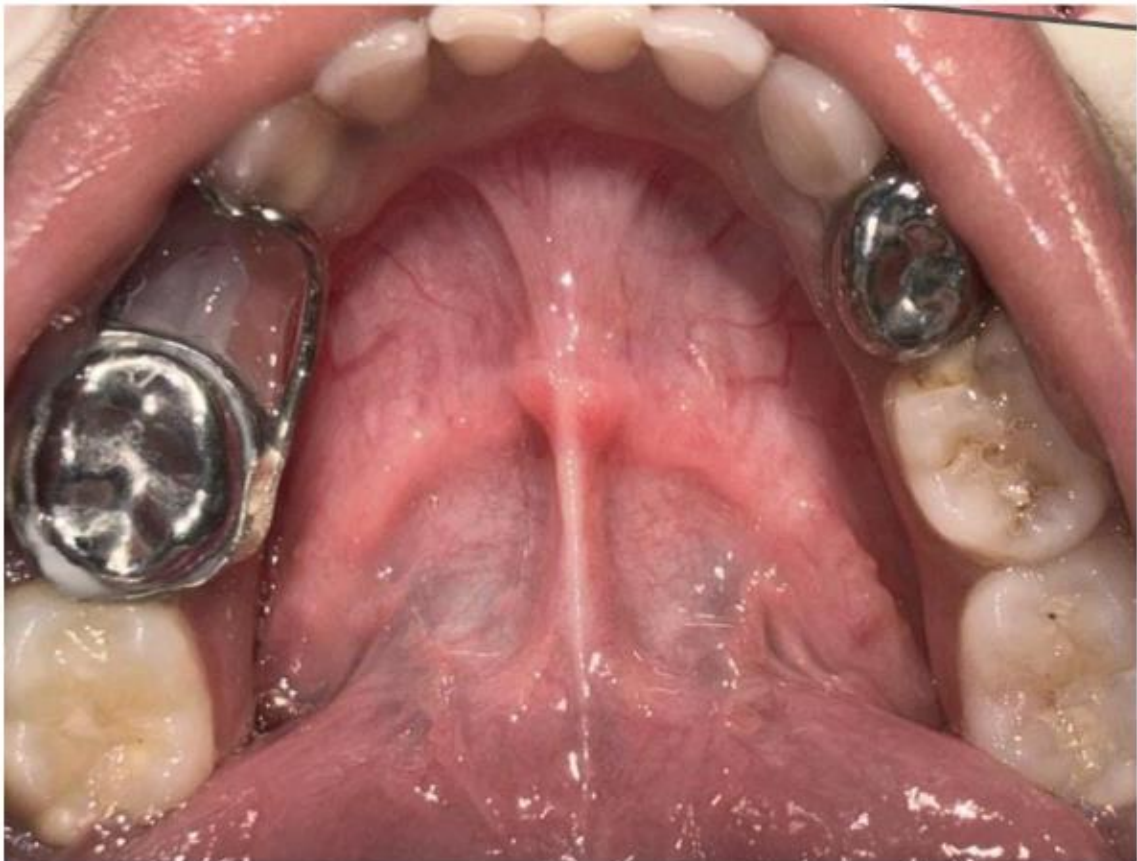Sex: Male



PRE-OPERATIVE UPPER AND LOWER INTRA-ORAL IMAGES



POST-OPERATIVE UPPER AND LOWER INTRA-ORAL IMAGES SHOWING BAND AND LOOP GIVEN IRT 65-63 AND 75-73, PULPECTOMY FOLLOWED BY SSC IRT 75, 84



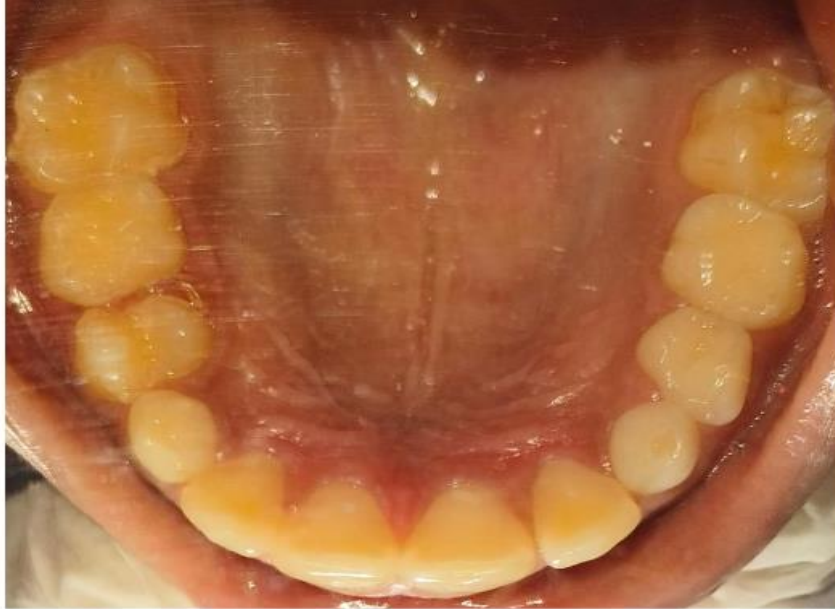

### 32. MANAGEMENT OF EDENTULOUS AREA IRT 84,85

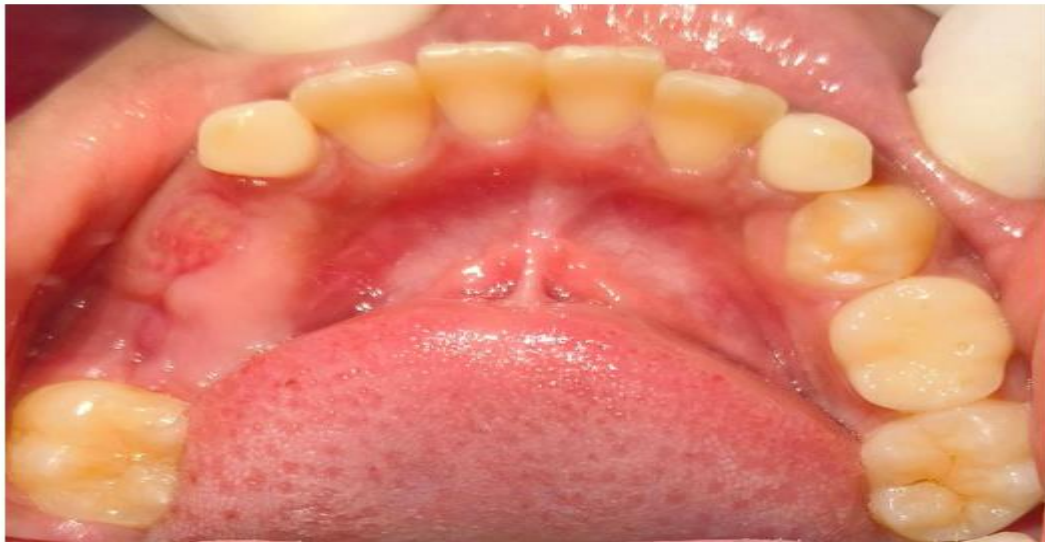Name : Hafeel

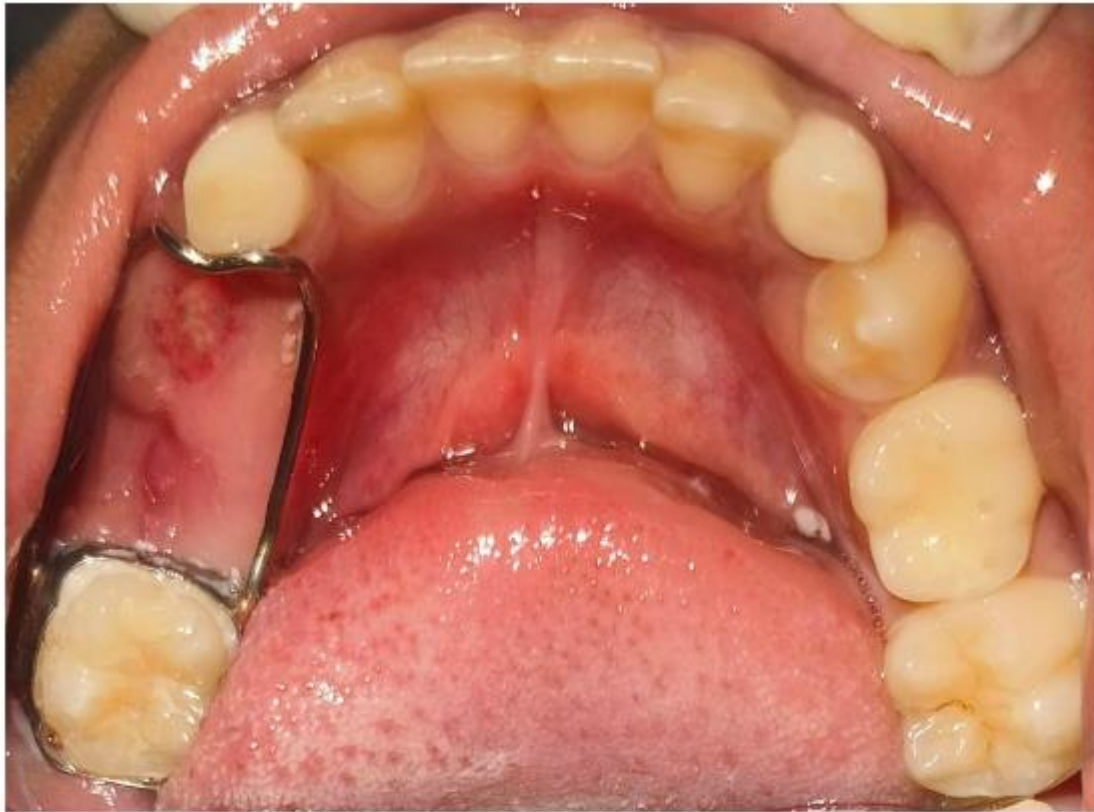Age: 10 years

Sex: Male



PRE-OPERATIVE UPPER AND LOWER INTRA-ORAL  
IMAGES





POST-OPERATIVE LOWER INTRA-ORAL IMAGES  
SHOWING LONG BAND AND LOOP IRT 46-83



**DEPARTMENT OF PEDODONTICS AND PREVENTIVE DENTISTRY**

**KVG Dental College and Hospital**

**Kurunjibagh, Sullia- 574327, Karnataka, India**

**Phone :08257- 233148, 230608, 231089, Extn: 1211, Fax : 08257-230148**

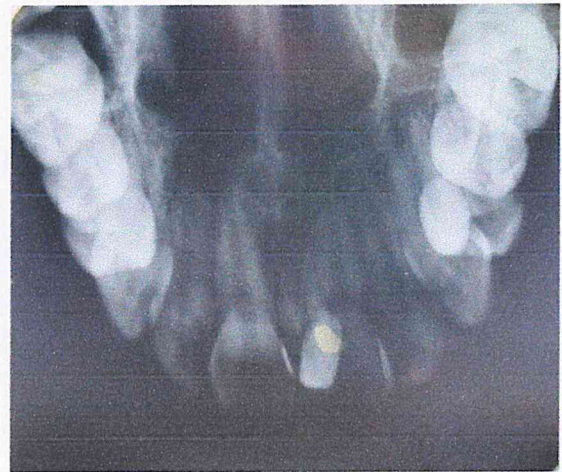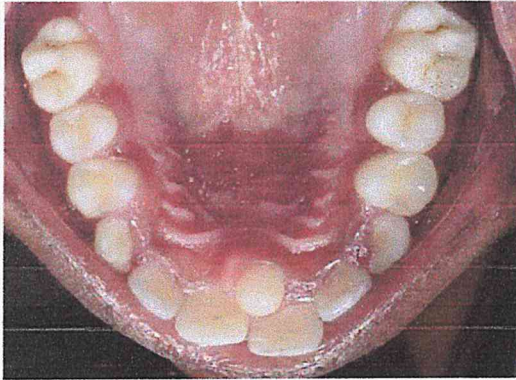
**Email -[kygpedo@gmail.com](mailto:kygpedo@gmail.com), website : [kygdentalcollege.org](http://kygdentalcollege.org)**

**33.SURGICAL EXTRACTION OF PALATALLY ERUPTED MESIODENS**

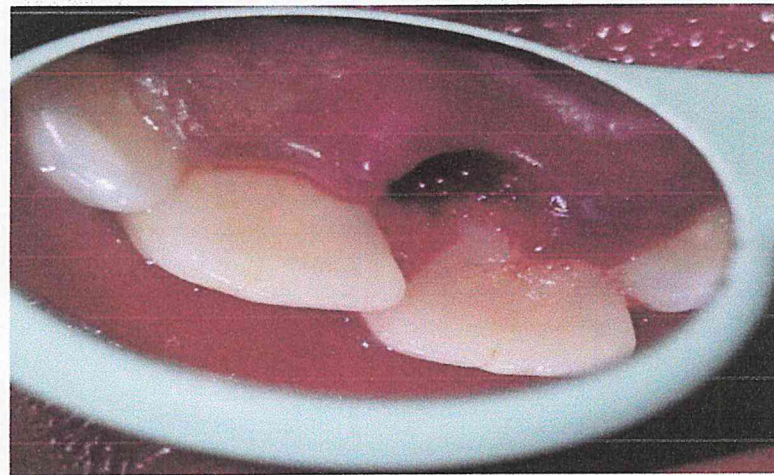
Name of the child: Pallavi

Age: 9 years


Gender: Female



PRE-OPERATIVE INTRAORAL IMAGE AND OCCLUSAL RADIOGRAPH TAKEN IRT <S21>



POST OPERATIVE INTRAORAL IMAGE AND IOPAR TAKEN IRT <S21>



**PRINCIPAL**  
**K.V.G Dental College & Hospital**  
**Kurunjibag, Sullia, D.K. - 574327**